

# Glutaryl-Coenzyme A dehydrogenase deficiency

Authors: Doctor S. Kölker<sup>1</sup> and Professor G.F. Hoffmann

Creation Date: June 2001

Update: June 2003

Scientific Editor: Professor Jean-Marie Saudubray

<sup>1</sup>Department of General Pediatrics, University Children's Hospital Heidelberg, Im Neuenheimer Feld 150, D-69120, Heidelberg, Germany. [Stefan\\_Koelker@med.uni-heidelberg.de](mailto:Stefan_Koelker@med.uni-heidelberg.de)

[Abstract](#)

[Key-words](#)

[Disease name and synonyms](#)

[Diagnosis criteria/definition](#)

[Differential diagnosis](#)

[Incidence](#)

[Clinical description](#)

[Treatment](#)

[Etiology](#)

[Diagnostic methods](#)

[Genetic counseling and prenatal diagnosis](#)

[Unresolved questions and outlook](#)

[References](#)

## Abstract

*Glutaryl-Coenzyme A (CoA) dehydrogenase deficiency (GDD) is an autosomal recessive neurometabolic disorder with an estimated incidence of 1:50,000 newborn Caucasians. It is caused by mutations in the glutaryl-CoA dehydrogenase gene localized on chromosome 19p13.2. Glutaryl-CoA dehydrogenase is a key mitochondrial enzyme in the catabolic pathways of the amino acids L-tryptophan, L-lysine, and L-hydroxylysine, that catalyzes the transformation of glutaryl-CoA into crotonyl-CoA. GDD is biochemically characterized by the accumulation of the dicarboxylic glutaric acids, 3-hydroxyglutaric and glutaconic acids, and glutarylcarnitine. It is clinically characterized by a distinct neuropathology but only exceptionally presents with classical metabolic symptomatology, such as hypoglycemia or acidosis. During a vulnerable period of brain development, usually between the ages 6 and 12 months, a acute encephalopathy results in bilateral striatal damage via an excitotoxic mechanism and leads to a severe dystonic dyskinetic movement disorder. The preencephalopathic phase is unremarkable but most often progressive macrocephaly is apparent. Analysis of urinary organic acids in suspected patients aims at early detection of GDD or, analysis of acylcarnitine from dried blood spots may potentially become implemented in neonatal screening programs. Following presymptomatic detection, dietary treatment, carnitine supplementation and prompt intervention to treat intercurrent illnesses can be initiated early and have been shown to prevent acute neuronal damage in the majority of affected children.*

## Key-words

Neurometabolic disorder, mitochondrial enzyme, encephalopathy, carnitine supplementation

---

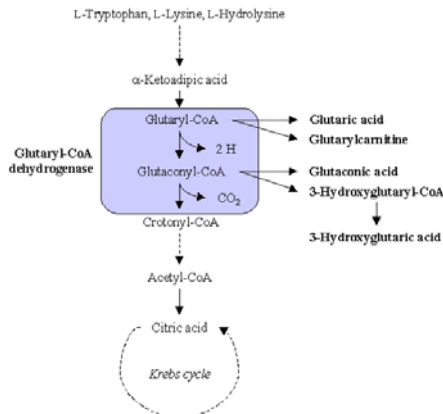
## Disease name and synonyms

Glutaryl-CoA dehydrogenase deficiency (GDD, MIM 231670) is an autosomal recessive inherited neurometabolic disorder (synonyms, glutaric aciduria or acidemia type I) first described by Goodman *et al* in 1975.

## Diagnosis criteria/definition

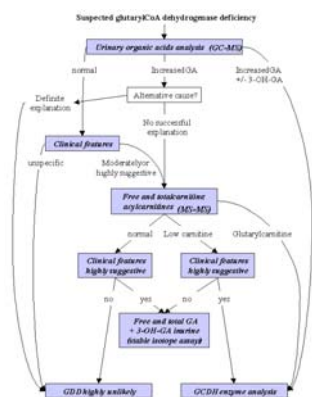
GDD is caused by homozygosity or compound heterozygosity for disease-causing mutations in the glutaryl-CoA dehydrogenase (GCDH) gene localized to chromosome 19p13.2 resulting in a GCDH deficiency. GDD is biochemically

characterized by the accumulation of upstream metabolites and their derivatives - in particular glutaric (GA), 3-hydroxyglutaric (3-OH-GA) and glutaconic acids - in body fluids and brain tissue of affected patients (Figure 1). GDD is clinically characterized by (progressive) macrocephaly and muscle hypotonia in preencephalopathic children followed by acute encephalopathy during infancy or early childhood. The latter results in acute striatal degeneration and, consequently, in severe dystonia and dyskinesia.



**Figure 1. Formation of glutaric and 3-hydroxyglutaric acids (with modifications from Liesert et al., 1999; Hoffmann & Zschocke, 1999).**

The diagnosis of GDD should be suspected in patients with macrocephaly or an extrapyramidal movement disorder beginning in childhood, and can be supported by further clinical features of varying diagnostic significance (Table 1). Diagnosis is confirmed by the detection of GA and 3-OH-GA acids in organic acid analyses of urine, blood or cerebrospinal fluid and/or by the detection of elevated glutarylcarnitine. The diagnosis of GDD is proven by pathologically low activity (Figure 2) in radiometric GCDH detection or by demonstration of two disease causing mutations by molecular genetic analysis.



GC-MS: gas chromatography-mass spectrometry.  
**Figure 2. Diagnostic flow chart for glutaryl-CoA dehydrogenase deficiency (with modifications from Baric et al., 1998)**

**Table 1. Clinical features suggestive of GDD deficiency (with modifications from Baric et al.<>**

1. Non-specific clinical features in preencephalopathic children  
 (Progressing) macrocephaly, frontal bossing  
 Delayed gross motor development (poor head control, hypotonic trunk, irritability)  
 Feeding difficulties
2. Moderately suggestive clinical features  
 Reye-like syndrome (acute metabolic encephalopathy)  
 Encephalitis-like encephalopathic seizures  
 (Athetoid) cerebral palsy  
 Sibling who died of or following an unexplained encephalopathic seizure (including sudden infant death syndrome)  
 Neuroradiological findings (subdural effusions, delayed myelination, subependymal pseudocysts)
3. Highly suggestive clinical features  
 Acute or progressive dystonic dyskinetic disorder  
 Specific neuroradiological findings (frontotemporal atrophy, isolated bilateral striatal degeneration)  
 Sibling who died suffering from acute bilateral striatal degeneration  
 Sibling with confirmed GDD

**Differential diagnosis**

Because GDD does not present clinically pathognomonic symptomatology and shares a variety of symptoms with other diseases, it is quite often misdiagnosed and most likely underdiagnosed. The most frequent misdiagnoses of patients with GDD include encephalitis, (dystonic) cerebral palsy, Reye's syndrome, battered child syndrome with chronic subdural effusions, acute familial striatal necrosis, familial megalencephaly, sudden infant death syndrome, postencephalitic Parkinsonism, and vaccine-induced brain injury.

**Incidence**

GDD has an estimated incidence of 1:30,000-40,000 newborn Caucasians. However, accurate epidemiological figures are not yet available because GDD is not yet generally included in routine neonatal screening programs. Thus, the diagnosis may be missed in many cases. GDD is much more common in some ethnic communities, such as the Old Order Amish Community in Pennsylvania, U.S.A., and the Saulteaux/Ojibway Indians in Canada (up to 1:300 neonates).

**Clinical description**

Within the organic acid disorders, GDD belongs to a distinct subgroup termed "cerebral" organic acid disorders, which present predominantly or exclusively with neurological symptoms, e.g. dystonia, dyskinesia, and ataxia, but only exceptionally with acidosis, hypoglycemia, myopathy or pancreatitis, the classical symptoms of organic acid disorders. Initially, affected neonates and infants show no or only mild physical signs, such as hypotonia with

prominent head lag, a high palate and irritability. The most suggestive sign in preencephalopathic children is (progressive) macrocephaly. During a vulnerable period of brain development (peak period: age 6 to 12 months) approximately 75% of undiagnosed and thus untreated children suffer an acute encephalitis-like encephalopathic seizures, usually precipitated by an intercurrent illness, such as febrile disease or even routine vaccination. If not treated adequately, irreversible bilateral destruction of susceptible brain regions, in particular the striatum, is induced. As a consequence, patients lose previously acquired motor skills and develop a dystonic dyskinetic disorder. Initially, intellectual functions are usually spared. If the disease remains undiagnosed and untreated, children develop generalized, chronic neurodegeneration. Apart from this "classical" presentation of GDD there are some rare reports of patients who remained asymptomatic without therapy. Furthermore, a recent report described adult-onset GDD, presenting with severe headaches (and additionally in one case with ataxia) and leukoencephalopathy. Therefore, GDD should be included in the differential diagnosis of leukoencephalopathy in young adults or adolescents.

### Treatment

Therapeutic (strategies/approaches) are aimed at preventing encephalopathic seizures and neurological deterioration. During the vulnerable period of brain development, dietary treatment with reduced intake of natural protein (total protein: 1.5-2.0 g/kg body weight/day), and specifically with restriction of lysine intake (age 0-12 months: 80-100 mg/kg body weight/day; age 1-6 years 50-80 mg/kg body weight/day) and reduction of tryptophan intake (age 0-12 months: 17-20 mg/kg body weight/day; age 1-6 years: 13-17 mg/kg body weight/day) using a specially formulated protein diet is implemented. Since acute encephalopathic crises have not been described after age 6 years, lysine restriction and tryptophan reduction by formulated protein diet is not indicated at school age. However, a restricted intake of natural protein should be continued.

Oral L-carnitine supplementation (age 0-12 months: 100 mg/kg body weight/day; age 1-6 years: 50-100 mg/kg body weight/day; age 7 years and over: 50 mg/kg body weight/day) is given to assure acyl-CoA transport across the mitochondrial membrane and prevent carnitine deficiency.

Riboflavin (100-200 mg/day), the cofactor of glutaryl-CoA dehydrogenase, is widely used, but its efficiency has not been proven in general. Riboflavin-sensitivity was only anecdotally observed in one patient. It may be tested

measuring the excretion of urinary glutaric and 3-hydroxyglutaric acids before and after administration of riboflavin.

Emergency treatment during febrile illness is aimed at preventing the development of catabolism of endogenous protein and to promote anabolism, which, consequently, should lead to the reversal of the former. Measures include an increase in the energy supply orally, nasogastrically or intravenously by 20-100% above the recommended daily requirements with carbohydrates (e.g. 20% dextrose orally or glucose intravenously) and fat (20% intralipid). Soluble insulin may be given to avoid hyperglycemia and to assure intracellular glucose uptake. Natural protein intake is stopped for 24-48 h and then reintroduced gradually. Feeding with specially formulated protein diet should be continued. L-Carnitine supplementation is doubled (100-200 mg/kg body weight/day). Glucose, electrolyte and fluid balance, urea, liver function, blood gases, and vital signs must be closely monitored. Observations made over the last decade have shown that this therapeutic strategy prevents brain damage in about 90% of prospectively treated patients. An additional administration of N-methyl-D-aspartate (NMDA) receptor antagonists, such as dextromethorphan, and antioxidants like  $\alpha$ -tocopherol are not widely accepted, although theoretically beneficial (see below). Future therapeutic strategies may also include the stabilization of mitochondrial energy metabolism (e.g. with creatine) as well as subtype-selective NMDA-receptor antagonists. Treatment of dystonic dyskinetic disorders in postencephalitic children remains unsatisfactory. Baclofen (1-2 mg/kg body weight/day) or benzodiazepines (e.g., clonazepam or diazepam) have been shown to reduce dystonia and sometimes to improve motor function. Older patients can benefit from botulinum injections or intrathecal application of baclofen. Anecdotal reports from clinical trials with other drugs, such as vigabatrin, ethosuccimide, L-dopa, and amantadine, revealed no sustained improvement of movement in our experience. Food intake is often impaired in neurologically affected children due to difficulties in chewing and swallowing, while energy demand is often increased because of high muscle tone and profuse sweating. Because the maintenance of good nutritional state is of utmost importance and has an impact on long-term morbidity and mortality, tube feeding is often advisable to guarantee sufficient energy supply.

### Etiology

*In vitro* and *in vivo* studies indicate that the accumulation of 3-OH-GA and GA organic acids is directly involved in the initiation of neuronal

damage in GDD patients. In particular 3-OH-GA is thought to act as a relevant endogenous neurotoxin via overstimulation of NMDA receptors and by inhibition of mitochondrial energy metabolism, which results in neuronal damage via excitotoxic mechanisms, including disturbance of intracellular calcium homeostasis and increased production of reactive oxygen species. Recent concepts also include the involvement of cytokines as factors triggering the onset of acute encephalopathy. Furthermore, NMDA receptor-independent mechanisms have been suggested, such as a depletion of the phosphocreatine pool.

### Diagnostic methods

Because GDD is a preventable cause of acute severe brain damage in early childhood, early diagnosis and treatment is of utmost importance (see also Figure 2). GA and 3-OH-GA can be detected through urinary organic acid analysis by gas chromatography-mass spectrometry (GC-MS). Some rare patients may require extremely sensitive determinations with stable-isotope dilution assays. Tandem mass spectrometry (MS-MS) allows the early detection of elevated glutaryl-carnitine in dried blood spots and is becoming increasingly used in neonatal screening programs. Neuroradiological investigations (cranial ultrasound, magnetic resonance imaging, cranial computed tomography) contribute to the diagnosis of GDD by detecting the characteristic abnormalities (e.g. frontotemporal atrophy, isolated bilateral striatal degeneration).

### Genetic counseling and prenatal diagnosis

Genetic counseling should be offered to affected families as the risk of GDD in future pregnancies is 25%. Mutation analysis of the parents and pedigree analysis should complete the diagnostic program. Prenatal diagnosis of affected fetuses is possible by demonstration of elevated GA concentrations of glutaric acid in amniotic fluid, measurement of GCDH activity in cultured amniotic cells or molecular analysis.

### Unresolved questions and outlook

Although there is experimental evidence that accumulating organic acids, in particular 3-OH-GA, are involved in the pathophysiology of GDD, many open questions remain. To optimize the management and treatment of affected children (regarding criteria of evidence-based medicine), a variety of investigations are currently performed, e.g. the investigation of GCDH-deficient mice. Furthermore, international database for this disease has been initiated (for further information please contact: [Stefan Koelker@med.uni-heidelberg.de](mailto:Stefan.Koelker@med.uni-heidelberg.de)).

### References

- Bähr O**, Mader I, Zschocke J, Dichgans J, Schulz JB (2002). Adult onset glutaric aciduria type I presenting with a leukoencephalopathy. *Neurology*; 59: 1802-1804.
- Baric I**, Zschocke J, Christensen E, Duran M, Goodman SI, Leonard JV, Müller E, Morton DH, Superti-Furga A, Hoffmann GF (1998) Diagnosis and management of glutaric aciduria type I. *J Inher Metab Dis*; 21:326-340.
- Bjugstad KB**, Goodman SI, Freed CR (2000) Age at symptom onset predicts severity of motor impairment and clinical outcome of glutaric acidemia type I. *J Pediatr*; 137: 681-686.
- Brismar NJ**, Ozand PT (1995) CT and MR of the brain in glutaric acidemia type I: a review of 59 published cases and a report of 5 new patients. *Am J Neuroradiol*; 16:675-683.
- Busquets C**, Merinero B, Christensen E, Gelpi JL, Campistol J, Pineda M, Fernandez-Alvarez E, Prats JM, Sans A, Arteaga R, Marti M, Campos J, Martinez-Pardo M, Martinez-Bermejo A, Ruiz-Falco ML, Vaquerizo J, Orozoco M, Ugarte M, Coll MP, Ribes A (2000) Glutaryl-CoA dehydrogenase deficiency in Spain: evidence of two groups of patients, genetically, and biochemically distinct. *Pediatr Res*; 48: 315-322.
- Christensen E** (1993) A fibroblast glutaryl-CoA dehydrogenase assay using detritiation of 3H-labelled glutaryl-CoA: application in the genotyping of the glutaryl-CoA dehydrogenase locus. *Clin Chim Acta*; 220: 71-80.
- deMello CF**, Kölker S, Ahlemeyer B, de Souza FR, Figuera MR, Mayatepek E, Krieglstein J, Hoffmann GF, Wajner M (2001) Intrastratial administration of 3-hydroxyglutaric acid induces convulsions and striatal lesions in rats. *Brain Res*; 916: 70-75.
- Goodman SI**, Markey SP, Moe PG, Miles BS, Teng CC (1975) Glutaric aciduria; a new inborn error of amino acid metabolism. *Biochem Med*; 12: 12-21.
- Goodman SI**, Stein DE, Schlesinger S, Christensen E, Schwartz M, Greenberg CR, Elpeleg ON (1998) Glutaryl-CoA dehydrogenase mutations in glutaric acidemia (type I): review and report of thirty novel mutations. *Hum Mutat*; 12: 141-144.
- Hoffmann GF**, Gibson KM, Trefz FK, Nyhan WL, Bremer HJ, Rating D (1994) Neurological manifestations of organic acid disorders. *Eur J Pediatr*; 153: S94-S100.
- Hoffmann GF**, Athanassopoulos S, Burlina AB, Duran M, de Klerck JBC, Lehnert W, Leonard JV, Monavari AA, Müller E, Muntau AC, Naughten ER, Plecko-Starting B, Superti-Furga A, Zschocke J, Christensen E (1996) Clinical course, early diagnosis, treatment, and prevention of disease in glutaryl-CoA

dehydrogenase deficiency. *Neuropediatrics*; 27: 115-123.

**Hoffmann GF**, Zschocke J (1999) Glutaric aciduria type I: From clinical, biochemical and molecular diversity to successful therapy. *J Inher Metab Dis*; 22: 381-391.

**Koeller DM**, Woontner M, Crnic LS, Kleinschmidt-DeMasters B, Stephens J, Hunt EL, Goodman SI (2002) Biochemical, pathologic and behavioral analysis of a mouse model of glutaric acidemia type I. *Hum Mol Genet*; 11: 347-357.

**Kölker S**, Ahlemeyer B, Krieglstein J, Hoffmann GF (2000a) Maturation-dependent neurotoxicity of 3-hydroxyglutaric and glutaric acids *in vitro*: a new pathophysiological approach to glutaryl-CoA dehydrogenase deficiency. *Pediatr Res*; 47: 495-503.

**Kölker S**, Ahlemeyer B, Krieglstein J, Hoffmann GF (2000b) Evaluation of trigger factors of acute encephalopathy in glutaric aciduria type I: fever and tumor necrosis factor-?. *J Inher Metab Dis*; 23: 359-362.

**Kölker S**, Ramaekers VT, Zschocke J, Hoffmann GF (2001) Acute encephalopathy despite early therapy in a patient with homozygosity for E365K in the glutaryl-CoA dehydrogenase gene. *J Pediatr*; 138: 277-279.

**Kölker S**, Ahlemeyer B, Krieglstein J, Hoffmann GF (2001) Contribution of reactive oxygen species to 3-hydroxyglutarate neurotoxicity in primary neuronal cultures from chick embryo telencephalons. *Pediatr Res*; 50: 76-82.

**Kölker S**, Ahlemeyer B, Hühne R, Mayatepek E, Krieglstein J, Hoffmann GF (2001) Potentiation of 3-hydroxyglutarate neurotoxicity following induction of astrocytic iNOS in neonatal rat

hippocampal cultures. *Eur J Neurosci*; 13: 2115-2122.

**Kölker S**, Köhr G, Ahlemeyer B, Okun JG, Pawlak V, Hörster F, Mayatepek E, Krieglstein J, Hoffmann GF (2002) Ca<sup>2+</sup> and Na<sup>+</sup> dependence of 3-hydroxyglutarate-induced excitotoxicity in primary neuronal cultures from chick embryo telencephalons. *Pediatr Res*; 52: 199-206.

**Kölker S**, Mayatepek E, Hoffmann GF (2002) White matter disease in cerebral organic acid disorders: clinical implications and suggested pathomechanisms. *Neuropediatrics*; 33: 225-231.

**Kyllerman M**, Skjeldal OH, Lundberg M, Holme I, Jellum E, von Döbeln U, Fossen A, Carlsson G (1994): Dystonia and dyskinesia in glutaric aciduria type I: clinical heterogeneity and therapeutic considerations. *Mov Disord*; 9: 22-30.

**Monavari AA**, Naughten ER (2000) Prevention of cerebral palsy in glutaric aciduria type I by dietary management. *Arch Dis Child*; 82: 67-70.

**Morton DH**, Bennett MJ, Seargeant LE, Nichter CA, Kelley RI (1991) Glutaric aciduria type I: a common cause of episodic encephalopathy and spastic paralysis in the Amish of Lancaster County, Pennsylvania. *Am J Med Genet*; 41: 89-95.

**Ullrich K**, Flott-Rahmel B, Schluff P, Musshoff U, Das A, Lücke T, Steinfeld R, Christensen E, Jakobs C, Ludolph A, Neu A, Röper R (1999) Glutaric aciduria type I: pathomechanism of neurodegeneration. *J Inher Metab Dis*; 22: 392-403.

**Zschocke J**, Quak E, Guldberg P, Hoffmann GF (2000) Mutation analysis in glutaric aciduria type I. *J Med Genet*; 37: 177-181.