

# Budd-Chiari Syndrome

Aurélie Plessier, M.D.,<sup>1</sup> and Dominique-Charles Valla, M.D.<sup>1,2,3</sup>

## ABSTRACT

Primary Budd–Chiari syndrome is related to thrombosis of hepatic veins or the terminal portion of the inferior vena cava. This rare disease is usually caused by multiple concurrent factors, including acquired and inherited thrombophilias. Half of the patients with primary Budd–Chiari syndrome are affected with a myeloproliferative disease, the recognition of which is largely based on the assessment of V617F Janus tyrosine kinase 2 (JAK2) mutation in peripheral granulocytes. A diagnosis of Budd–Chiari syndrome should be considered in any patient presenting with acute or chronic liver disease, as clinical manifestations are extremely diverse. Spontaneous outcome in symptomatic patients is poor. Diagnosis can be made in most patients noninvasively when imaging shows venous obstruction and/or collaterals. A treatment strategy is recommended where anticoagulation is given first, followed by angioplasty when appropriate, then TIPS in patients not responding to previous measure, and finally liver transplantation. This strategy has achieved 5-year survival rates close to 90%.

**KEYWORDS:** Myeloproliferative disease, thrombosis, thrombophilia, transjugular intrahepatic portosystemic shunt, anticoagulation, angioplasty, liver transplantation

In the past, the term Budd–Chiari syndrome has been used to designate various entities, which was occasionally misleading. Recently, however, international panels have agreed that Budd–Chiari syndrome (BCS) be used as an eponym for hepatic venous outflow tract obstruction, whatever the level or the mechanism of obstruction.<sup>1,2</sup> Cardiac and pericardial diseases are excluded from this definition as well as sinusoidal obstruction syndrome occurring in the context of an exposure to toxic substances. BCS is further separated into secondary BCS when related to compression or invasion by a lesion originating outside the veins (benign or malignant tumor, abscess, cyst, etc.); and primary BCS when related to a primarily venous disease (thrombosis or phlebitis). Obstruction of the hepatic venous outflow tract can be classified according to its location: small hepatic veins (HVs), large HVs, inferior vena cava (IVC), and combined obstruction of large HVs and IVC.<sup>3</sup>

## EPIDEMIOLOGY

Available data are scarce. The prevalence of BCS appears to differ by several orders of magnitude according to the area. In Nepal, BCS represents the leading cause for hospital admission for liver disease,<sup>4</sup> whereas it appears to be very rare in Japan and in France.<sup>5</sup> The level of obstruction might also differ according to the area. As a rule, pure IVC or combined IVC/HV block has predominated in Asia, whereas pure HV block has predominated in Western countries.<sup>5</sup> There was a slight predominance of males, and a median age 45 years in Asia, while there was a marked preponderance of females, and a younger median age (35 years) in the West. However, a recent European survey showed an equal distribution of pure HV block and combined IVC/HV block,<sup>6</sup> as well as a trend toward an increased proportion of males and an older age at diagnosis.<sup>6</sup> The reasons for these geographical differences and temporal changes

<sup>1</sup>Service d'Hépatologie, Hôpital Beaujon; <sup>2</sup>INSERM U773, Hôpital Beaujon, Clichy, France; <sup>3</sup>Université Denis Diderot-Paris 7, Paris, France.

Address for correspondence and reprint requests: Dominique-Charles Valla, M.D., Service d'Hépatologie, Hôpital Beaujon, 100, Boulevard du Général Leclerc, 92118 Clichy Cedex, France (e-mail: [dominique.valla@bjn.aphp.fr](mailto:dominique.valla@bjn.aphp.fr)).

Vascular Diseases of the Liver; Guest Editor, Dominique-Charles Valla, M.D.

*Semin Liver Dis* 2008;28:259–269. Copyright © 2008 by Thieme Medical Publishers, Inc., 333 Seventh Avenue, New York, NY 10001, USA. Tel: +1(212) 584-4662.

DOI 10.1055/s-0028-1085094. ISSN 0272-8087.

in Europe are unclear. Environmental factors such as oral contraceptive use (rare in Asia) and poor nutrition (common in Nepal), discussed below, have been incriminated.<sup>4,5</sup>

## CAUSAL FACTORS

### Secondary Budd–Chiari Syndrome

Hepatocellular carcinoma, renal adenocarcinoma, adrenal adenocarcinoma, primary hepatic hemangiosarcoma, epithelioid hemangioendothelioma, sarcoma of IVC and right atrial myxoma, and alveolar hydatid disease may cause BCS through invasion of the venous outflow.<sup>7,8</sup> Parasitic and nonparasitic cysts, and abscesses can produce compression and thrombosis of the hepatic venous outflow tract.<sup>9,10</sup> Large nodules of focal nodular hyperplasia in a central location may cause compression of the hepatic veins.<sup>11</sup> Compression or kinking of the hepatic veins can occur following hepatic resection or transplantation.<sup>12,13</sup> BCS may occur following blunt abdominal trauma, either from compression by intrahepatic hematoma, IVC thrombosis related to trauma, or herniation of the liver through a ruptured diaphragm.<sup>14–16</sup>

### Primary Budd–Chiari Syndrome

Most studies have yielded similar results: an underlying prothrombotic disorder (or thrombophilia), or an established risk factor for venous thrombosis, is found in a majority of patients,<sup>17–26</sup> as discussed elsewhere in this issue (Primignani and Mannucci, pp. 293–301). Recent advances in diagnostic tools have confirmed that myeloproliferative diseases account for half of BCS cases,<sup>27–29</sup> even though most patients with myeloproliferative disease when they present with BCS have normal or low blood cell counts of peripheral blood. Factor V Leiden mutation, antiphospholipid syndrome, and G20210A prothrombin gene mutation are the next most common prothrombotic factors in BCS patients. The role of hyperhomocysteinemia, and of primary deficiency in protein C, protein S, or antithrombin remains unclear because liver disease obscures recognition of these disorders. Paroxysmal nocturnal hemoglobinuria is an extremely rare condition, which is complicated by Budd–Chiari syndrome in up to 30% of patients, so that it accounts for ~5% of BCS patients. Behcet's disease, where prevalent, has accounted for the majority of BCS patients.<sup>30</sup> Hypereosinophilic syndrome,<sup>31</sup> granulomatous venulitis,<sup>32</sup> and ulcerative colitis<sup>33</sup> appear to be additional risk factors for BCS. Pregnancy also appears to be a risk factor for BCS, based on the temporal association between both conditions,<sup>34–36</sup> although no case–control study has been performed to quantify this risk.

Environmental risk factors mainly consist of oral contraceptive use in Western countries<sup>18,37</sup> and factors associated with a very poor standard of living in Asia.<sup>4</sup>

Overall, an underlying risk factor for thrombosis has been found in up to 87% of BCS patients.<sup>38</sup> A combination of several causal factors is demonstrated in ~25% of patients, where routinely investigated.<sup>17,18,38</sup> A combination with another causal factor is particularly common in patients with heterozygous factor V Leiden,<sup>20</sup> or in oral contraceptive users<sup>37</sup> or pregnant women.<sup>36</sup> It is remarkable that the local factor responsible for development of thrombosis in the hepatic venous outflow tract, a highly unusual site, remains unidentified in most patients. Therefore, once a tumor has been ruled out with imaging, a comprehensive work-up for prothrombotic diseases should be performed in all patients with BCS, whatever the location of the obstruction. Furthermore, an association of several prothrombotic conditions should be investigated. However, in patients with a decreased level of coagulation factors reflecting a decreased synthetic function of the liver, the value of assessing plasma levels of protein C, protein S, antithrombin, and homocysteine is questionable as the results will be difficult to interpret.

## MANIFESTATIONS AND COURSE

In most cases, the underlying disorders causing thrombosis of the hepatic venous outflow tract are unrecognized at presentation. Presentation ranges from complete absence of symptoms to fulminant hepatic failure, through acute (rapid) or chronic (progressive) development of symptoms over weeks to months before diagnosis is made. The apparent age of the macroscopic and microscopic damage to the veins or the liver may differ from the apparent duration of symptoms.<sup>34,39</sup> Asymptomatic Budd–Chiari syndrome accounts for 15 to 20% of cases.<sup>40</sup> The absence of symptoms is strongly associated with large hepatic vein collaterals.<sup>40</sup> Classical manifestations of BCS include fever, abdominal pain, ascites, and leg edema. Jaundice, gastrointestinal bleeding, and hepatic encephalopathy are less common. Serum transaminases and alkaline phosphatase can be normal or increased. Levels of serum albumin, serum bilirubin and prothrombin can be normal or abnormal, and in some patients markedly abnormal. Protein level in ascitic fluid varies from patient to patient. Protein content above 3.0 g/dL is evocative of BCS, cardiac or pericardial disease. The course of manifestations can be steady, or marked by exacerbations and remissions. The disease can run a long insidious course, or a short period of prodrome followed by a rapid downhill course. Portal venous obstruction is common in patients with severe forms of the disease.<sup>41–43</sup>

Thus, a diagnosis of BCS must be considered in all patients with an acute or chronic liver disease,

especially when common causes for liver disease have been ruled out. In other words, an assessment of the patency of IVC and HV should be part of the routine evaluation of patients with liver diseases.

Natural history of symptomatic BCS appears to be almost universally fatal. In a British cohort dating back to the 1960s, when no specific therapy was yet available, 90% of patients had died by 3 years.<sup>44</sup> Main causes of death are intractable ascites with emaciation, gastrointestinal bleeding, and liver failure.

## DIAGNOSIS

X-ray venography has been a reference for the evaluation of the hepatic veins. However, for diagnostic purposes, noninvasive imaging provides evidence for BCS in most patients. Sonographic findings are well related to pathological<sup>45</sup> and venographic findings.<sup>46-48</sup> The following features have been considered specific for hepatic vein obstruction on color Doppler imaging and pulse Doppler analysis of hepatic vein wave form: (1) a large hepatic vein appearing void of flow-signal, or with a reversed, or turbulent flow; (2) large intrahepatic or subcapsular collaterals with continuous flow connecting the hepatic veins or the diaphragmatic or intercostal veins; (3) a spider-web appearance usually located in the vicinity of hepatic vein ostia, together with the absence of a normal hepatic vein in the area; (4) an absent or flat hepatic vein wave form without fluttering; and (5) a hyperechoic cord replacing a normal vein. The absence of visualization or tortuosity of the hepatic veins at gray-scale real-time sonography albeit with flow signals at Doppler imaging are common, but not specific; they are also observed in advanced cirrhosis of other origin. A distinctive feature for BCS, however, is the association with intrahepatic or subcapsular hepatic venous collaterals, which is found in over 80% of the cases. The major advantages of ultrasound study, beyond sensitivity and specificity, are relatively low cost, wide availability, complete lack of harm, and minimal technical difficulty. Limitations lie in patient's body habitus, which may preclude complete sonographic evaluation, and insufficient expertise of the operator.

Spin-echo and gradient-echo magnetic resonance imaging (MRI) sequences and intravenous gadolinium injection allow for visualization of obstructed hepatic veins and IVC, intrahepatic or subcapsular collaterals.<sup>45,49</sup> MRI is not as effective as sonography in demonstrating intrahepatic collaterals,<sup>45</sup> whereas it might be more accurate than direct inferior venacavography for characterizing solid endoluminal material. MRI is a minimally invasive investigation. Some contrast agents may alter kidney function. The techniques can be standardized and the results are not operator-dependent.

With computed tomography (CT), failure to visualize the hepatic veins is considered suggestive for

hepatic vein obstruction. However, there were problems of false-positive and indeterminate results in ~50% of the cases.<sup>45</sup> There have been no clinical studies using the most recent techniques for CT. Although CT is minimally invasive, there is exposure to radiation, and a risk for renal toxicity and reaction to iodinated products.

Direct evidence for thrombosis is rarely obtained at needle liver biopsy. Nevertheless, liver biopsy remains the sole means to diagnose the rare form of BCS due to involvement of the small hepatic veins with patent large veins,<sup>3</sup> although differentiation of this form from sinusoidal obstruction syndrome is not always feasible.<sup>3,50</sup> Liver biopsy shows indirect, but strong, evidence for hepatic venous outflow tract obstruction: congestion, liver cell loss, and fibrosis in the centrilobular area are considered characteristic features.<sup>3</sup> There may be considerable variation in the degree of these changes from one area to the other. The main differential diagnoses are heart failure, constrictive pericarditis, circulatory failure, and sinusoidal obstruction syndrome. Although venular and perivenular fibrosis without congestion is occasionally found in patients with long-standing suprahepatic inferior vena cava obstruction,<sup>51</sup> the absence of congestion in the centrilobular area is a strong argument against a diagnosis of hepatic vein thrombosis. Serious consideration should be given to the risk of bleeding from the puncture site in these patients who are likely to receive early anticoagulation or emergent thrombolytic therapy.

Other indirect signs of BCS may be of help for diagnosis. Caudate lobe hypertrophy is found in ~75% of patients.<sup>45,52</sup> However, enlargement is common as well in many cases of cirrhosis of other origin.<sup>53</sup> A characteristic pattern of parenchymal perfusion can be demonstrated using CT or MRI following bolus intravenous injection of contrast medium. This pattern consists of early homogeneous central enhancement (particularly at the level of the caudate lobe) together with delayed patchy enhancement of the periphery of the liver and prolonged retention of the contrast medium in the periphery.<sup>45,54,55</sup> This heterogeneity is related to uneven portal perfusion. It is also observed in other situations where portal venous perfusion is compromised.<sup>53,56</sup> One of these situations, constrictive pericarditis, mimics hepatic venous obstruction clinically, and can be missed at echocardiography.<sup>57</sup>

Nodular regenerative hyperplasia, and macroregenerative nodules (enhancing at the arterial phase of contrast injection) are common in patients with longstanding BCS.<sup>41,42</sup> These architectural changes appear to be strongly related to the obstruction of the corresponding portal vein branch and to increased arterial inflow.<sup>41,42</sup> Hepatocellular carcinoma has been rarely reported and is mainly observed in patients with long-standing disease, particularly in relationship to suprahepatic inferior vena cava obstruction.<sup>20,58-60</sup>

## TREATMENT

### Underlying Risk Factors for Thrombosis

Oral contraceptives are generally considered to be contraindicated in patients with BCS. It is not clear whether pregnancy should be considered contraindicated in patients whose underlying risk factors for thrombosis are controlled, as there are reports of successful and uncomplicated pregnancies in patients with BCS given anticoagulation during the whole pregnancy.<sup>36,61</sup>

It is logical to treat underlying myeloproliferative diseases. Neither the threshold in blood cell counts where treatment should be initiated, nor the target counts to be reached with therapy, have been assessed yet. Low-dose acetyl salicylic acid has been shown to be beneficial to prevent arterial disease in patients with polycythemia vera, but data on venous thrombosis are less clear.<sup>62</sup> It is worth noting that acetyl salicylic acid use is a risk factor for gastrointestinal bleeding in patients with portal hypertension.<sup>63</sup> For most other risk factors for BCS, the only available treatment is anticoagulation.

### Anticoagulation Therapy

The rationale for anticoagulation in patients with primary BCS is based on the high prevalence of underlying thrombophilia in such patients, and on the proven efficacy of this treatment for deep vein thrombosis.<sup>64</sup> Indefinite anticoagulation therapy is generally recommended after an episode of idiopathic deep venous thrombosis in patients in whom a permanent risk factor is present and when thrombophilia is not curable.<sup>64</sup> However, direct support for anticoagulation therapy in BCS patients is lacking. There have been no prospective randomized controlled trials of anticoagulation in patients with BCS. Two retrospective studies with multivariate analysis have attempted to evaluate the impact of anticoagulation on mortality for BCS.<sup>65,66</sup> The findings supported a beneficial effect of anticoagulation, although this benefit might be limited to the subgroup of patients with less severe disease at baseline. Neither of these 2 studies included the presence of an underlying risk factor for thrombosis in the analysis. Further circumstantial evidence for anticoagulation stems from (1) the improved survival observed in all cohorts where, among other treatments, anticoagulation was used<sup>66,67,68</sup>; and (2) the improved results of liver transplantation<sup>69,70</sup> or hepatic vein angioplasty<sup>71</sup> when anticoagulation medication was given.

There has been no report of bleeding-related death in BCS patients on anticoagulation, but there have been few studies on this particular issue. A recent study disclosed a high rate of anticoagulation-related complications in patients undergoing transhepatic interventional therapy. Moreover, a surprisingly high rate

of heparin-induced thrombocytopenia was observed, mainly with unfractionated heparin.<sup>72</sup> Therefore, when anticoagulation of short duration is needed, low-molecular-weight heparin should be preferred. For long-term therapy, vitamin K antagonists have been used aiming at an international normalized ration (INR) of 2 to 3.<sup>67,68</sup>

### Thrombolysis

The limited amount of available data on efficacy and tolerance of pharmacologic thrombolysis has been recently reviewed, and found to be inconclusive.<sup>73,74</sup> There is some indication that in situ infusion of thrombolytic agents is associated with sustained patency of recently thrombosed veins when thrombolysis is coupled with restoration of a high blood flow velocity by means of angioplasty or stenting.<sup>74</sup>

### Treatment for Portal Hypertension

Guidelines for the management of portal hypertension-related complications in patients with cirrhosis of other causes have usually been applied to BCS patients. However, circulatory changes seen in BCS patients differ from those seen in patients with cirrhosis of other causes. BCS patients have activated vasoactive neuro-humoral systems and expanded plasma volume, but they do not exhibit systemic vasodilation or increase in cardiac output.<sup>75</sup> Therefore, it remains to be assessed whether  $\beta$  adrenergic blockade or endoscopic ligation should be preferred as a first line of therapy in patients that are not a candidate for angioplasty or transjugular intrahepatic portosystemic shunting (TIPS).

### Angioplasty and Stenting

The rationale for recanalization has been to decompress the liver without compromising, and even with restoring, hepatic blood flow. Patients with focal or segmental obstruction of the hepatic venous outflow tract are theoretically eligible for recanalization. Short-length stenosis of the cephalad portion of one or several large hepatic veins is present in 25 to 30% of patients with pure hepatic vein block.<sup>76</sup> Likewise, a so-called membranous obstruction of the suprahepatic IVC (actually a focal or segmental obliteration or stenosis) is found in up to 60% of the patients with IVC block.<sup>8</sup> In most patients with suprahepatic IVC obstruction, the ostium of at least one major hepatic vein is occluded or the hepatic vein termination into the IVC is abnormal.<sup>8</sup>

Surgery for hepatic vein or IVC angioplasty and for hepatoatrial anastomosis has been progressively abandoned with the development of percutaneous procedures. Data on percutaneous angioplasty with or without stenting consist of a limited number of retrospective uncontrolled studies on cohorts of diverse size.<sup>71,77-97</sup>

Percutaneous angioplasty by means of balloon or Gruntzig catheters has usually been performed through a transluminal transvenous route (either femoral or jugular) for HVs or IVC, whether or not a stent was primarily inserted. A transhepatic approach to recanalization with stenting has also been used when a long segment of a HV was occluded.

Severe procedure-related complications seem to be rare with percutaneous transluminal angioplasty alone (immediate thrombosis of the veins or pulmonary embolism, generally amenable to thrombolytic therapy), but might be more frequent with stent insertion through the transluminal route (stent migration into the heart), and with the transhepatic approach (bleeding). After successful insertion, rapid improvement in signs, symptoms, and liver function has generally been mentioned. Reobstruction appears to be more common in patients undergoing primary angioplasty alone than in patients undergoing primary stenting. Prognostic factors for reobstruction have not been assessed. Periprocedural and total mortality appear to be low and not related to the procedure. However, no evaluation based on initial severity of the disease is possible. It should be remembered that patients with short-length stenoses of the hepatic veins, eligible for, but untreated with, recanalization procedures have a better outcome than the other patients.<sup>76</sup>

### Portosystemic Shunting

The rationale for side-to-side portosystemic shunting has been to decompress the liver using the portal venous system as an outflow tract, thus at the expense of a suppression of portal venous inflow. Depending on the patency of the IVC, and on technical limitation related to caudate lobe enlargement, several variants of surgical side-to-side shunting have been used. A combination of porto- or meso-caval shunts with IVC bypass or IVC stenting has been used to cope with the compression of IVC by caudate lobe enlargement. Overall perioperative mortality has been high, averaging 25% (reviewed by Langlet and Valla<sup>98</sup>). The rate of shunt dysfunction due to early or late thrombosis or to late stenosis has reached 30% in series with long-term follow-up.<sup>99,100</sup> Surgical portosystemic shunting has been assessed in 4 multicenter, retrospective, multivariate analyses, which failed to show any impact on survival after adjustment for independent prognostic factors.<sup>65,66,101,102</sup> In these 4 studies, surgical shunting was considered on an intention-to-treat basis, i.e., without consideration for shunt patency. Recent data show that maintenance or reestablishment of good shunt function is crucial for long-term survival.<sup>103</sup> Shunt dysfunction may be related to stenosis of intrahepatic IVC (which is amenable to stenting),<sup>80,103,104</sup> to shunt stenosis (amenable to percutaneous transluminal angioplasty and stenting),<sup>78,80,105</sup>

and to shunt or portal vein thrombosis (amenable to *in situ* thrombolysis).<sup>105</sup> Risk factors for shunt dysfunction appear to be the use of long prosthetic grafts.<sup>103,106</sup> Routine anticoagulation did not prevent shunt dysfunction from occurring.<sup>103,107</sup> Whether anticoagulation can still have a protective effect cannot be assessed from the limited data available.<sup>108</sup>

TIPS have been increasingly used for BCS treatment in recent years.<sup>68,72,79,93,95,96,109–120</sup> Indications were generally claimed to be manifestations unresponsive to medical therapy. Insertion was successful in over 80% of cases. After an average follow-up of ~24 months, dysfunction was reported in over half of patients. One-month mortality rate was <10%. Overall mortality rate was ~20%; ~10% of patients underwent liver transplantation. In some patients, however, TIPS was used as a bridge to planned liver transplantation, whereas other patients, whose condition improved, were not listed or were withdrawn from the transplantation waiting list. In most surviving and not transplanted patients, rapid improvement in general condition, control of ascites, and liver function has generally been described. There has been no attempt at comparing the outcome following TIPS insertion to that following surgical shunting, after adjustment for prognostic factors. TIPS dysfunction as well as clinically significant events were less common when using polytetrafluoroethylene- (PTFE-) covered stents than uncovered stents.<sup>121</sup> A higher than expected incidence of procedure-related bleeding has been reported following TIPS insertion for treatment of BCS as compared with other chronic liver disease.<sup>72,115</sup> A learning curve effect for success and complication rates, not for mortality, has been observed.<sup>72</sup> The incidence of post-TIPS encephalopathy appears to be low,<sup>68,121</sup> but this contention has to be assessed.

### Liver Transplantation

Data from 84% of the patients transplanted for BCS in the European liver transplant registry between 1988 and 1999 have recently been analyzed.<sup>122</sup> Half the patients included in the European transplant survey belonged to Rotterdam prognostic class III (with the worst baseline prognosis<sup>66</sup>). Overall actuarial survival was 76% at one year, 71% at 5 years, and 68% at 10 years.<sup>122</sup> This survival is almost identical to that in the intermediate class of risk score (Rotterdam class II) from a contemporary U.S.–Dutch–French cohort where a minority of patients underwent transplantation. In surveys of consecutive patients transplanted for BCS, 27 out of 142 patients (19%) had been transplanted following portosystemic shunting.<sup>69,70,110,117,123–128</sup> Likewise, in the European survey, 24% of patients had undergone TIPS or surgical shunting.<sup>122</sup> Previous surgical shunting or TIPS, together with high serum creatinine and bilirubin levels, was an independent marker of a poor outcome following

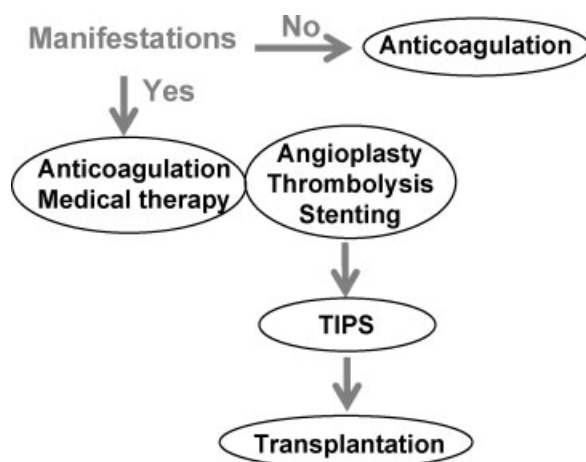
transplantation in the European survey,<sup>122</sup> but not in the U.S. database.<sup>129</sup>

A favorable impact of early and prolonged anticoagulation on the results of liver transplantation has been suggested. In the European survey, 85% of patients received anticoagulation posttransplant. Venous thrombosis at various sites recurred in 27 patients (11%). Mortality was 40.7% in patients with recurrence. Hemorrhage attributed to anticoagulants was observed in 27 patients (11%). Two patients with intracranial bleeding died and the mortality attributed to anticoagulants was 1%.<sup>122</sup>

Some data indicate that for patients with myeloproliferative disease, a strategy combining hydroxyurea and aspirin for prevention of thrombotic events might be as effective as anticoagulation.<sup>130</sup> There is no indication that within 10 years of transplantation, there is a significant increase in the risk of malignant transformation of underlying myeloproliferative disease as compared with natural history in nontransplant patients.

### Treatment Strategy

Consensus statements have been elaborated by international expert panels in 2002<sup>1</sup> and 2005.<sup>2</sup> In these documents, a strategy depicted in Fig. 1 was proposed, consisting of the following graded approach: (1) anticoagulation, treatment of underlying condition, and symptomatic treatment for complications of portal hypertension in all patients with primary BCS; (2) active search for venous lesions amenable to angioplasty/stenting; (3) in patients not suited for, or unresponsive to angioplasty/stenting, insertion of a TIPS should be considered; (4) and in patients unresponsive to TIPS, liver transplantation should be considered. Two recent



**Figure 1** A strategy recommended for the management of Budd-Chiari syndrome patients, using a stepwise implementation of therapeutic options by order of increasing invasiveness. Recourse to a more invasive option is indicated by technical failure or absence of clinical response to a previous, less invasive option.

clinical studies provide support to the above strategy. The outcome in these two cohorts (5-year survival over 85%) was clearly better than in cohorts managed mainly with medical therapy or surgical shunting. In particular, the improvement seen in all prognostic classes was most marked in patients with the poorest baseline prognosis.<sup>131</sup> From the relatively limited, but consistent data available, it appears that the first step of the strategy (medical therapy) is associated with steady improvement in 10 to 20% of patients without any need for additional therapy.<sup>72,95,132</sup> Next, in Western countries where pure hepatic vein block predominates, percutaneous recanalization appears to achieve a complete response in an additional 10 to 20% of patients; TIPS in an additional 65%; and liver transplantation in the rest. By contrast, in Asia where suprahepatic IVC block predominates, percutaneous recanalization can be expected to achieve a complete response in 60% of patients, whereas the place of TIPS, derivative surgery, and transplantation remains unclear.<sup>86,95</sup>

It is obvious that a precise delineation of the obstacle is crucial for planning therapy. For this purpose, direct venography with measurement of pressure gradient across stenoses, is usually necessary to complement the information provided by noninvasive imaging. This invasive procedure can be performed as the first part of a recanalization or TIPS insertion procedure.

### CURRENT OUTCOME AND PROGNOSIS

There has been continued improvement over the last 4 decades. In the most recently reported cohorts, overall 5-year survival rates over 80% have been achieved.<sup>66,68,72,113,118</sup>

Serum albumin, bilirubin, prothrombin, ascites, and encephalopathy, or their combination as Pugh score, have generally been found to be independent prognostic factors.<sup>65,66,95,101,102</sup> Corresponding prognostic scores have been elaborated. These scores are most useful for clinical studies, but not relevant to individual management. Once components of the Child Pugh score were taken into account, neither the site of hepatic venous outflow tract obstruction, nor histological variables appear to bear independent prognostic value.<sup>65,66,95,101,133</sup>

Current concern for long-term outcome focuses on the risks of late development of hepatocellular carcinoma,<sup>60</sup> and of aggravation or transformation of underlying blood disease.<sup>134</sup>

### SPECIAL GROUPS

#### Children

Data on BCS in children are scarce. Series of consecutive cases date back to the early 1990s.<sup>34,135-137</sup> There appears to be a predominance of obstruction at the level

of suprahepatic inferior vena cava. Etiology remains unclear as underlying prothrombotic diseases have not been routinely investigated. There are, however, isolated case reports of an association with factor V Leiden or prothrombin gene mutation, antiphospholipid syndrome, or celiac disease. Surgical as well as percutaneous therapy (TIPS or recanalization), and thrombolysis have been claimed beneficial in selected cases.

### Patients with Combined Portal Vein and Hepatic Venous Outflow Tract Obstruction

Extrahepatic portal vein thrombosis has been found in ~15% of unselected BCS patients.<sup>43,133</sup> Disease is usually more severe in these patients than in those with a patent extrahepatic portal vein. TIPS, however, has been possible and apparently effective in a handful of patients,<sup>138</sup> whereas surgical portosystemic shunting and liver transplantation apparently had poor results.<sup>43,133</sup> Portal vein thrombosis was present pretransplant in 47 of 248 patients in the European survey on transplantation; however, the impact of portal vein thrombosis on the outcome of liver transplantation was not reported.<sup>122</sup>

### ABBREVIATIONS

BCS	Budd–Chiari syndrome
CT	computed tomography
HV	hepatic vein
IVC	inferior vena cava
MRI	magnetic resonance imaging
TIPS	transjugular intrahepatic portosystemic shunt

### REFERENCES

- Janssen HL, Garcia-Pagan JC, Elias E, Mentha G, Hadengue A, Valla DC. Budd-Chiari syndrome: a review by an expert panel. *J Hepatol* 2003;38:364–371
- de Franchis R. Evolving Consensus in Portal Hypertension Report of the Baveno IV Consensus Workshop on methodology of diagnosis and therapy in portal hypertension. *J Hepatol* 2005;43(1):167–176
- Ludwig J, Hashimoto E, McGill D, Heerden JV. Classification of hepatic venous outflow obstruction: ambiguous terminology of the Budd-Chiari syndrome. *Mayo Clin Proc* 1990;65:51–55
- Shrestha SM, Okuda K, Uchida T, et al. Endemicity and clinical picture of liver disease due to obstruction of the hepatic portion of the inferior vena cava in Nepal. *J Gastroenterol Hepatol* 1996;11:170–179
- Valla D. Hepatic venous outflow tract obstruction etiology: Asia versus the West. *J Gastroenterol Hepatol* 2004;19:S204–S211
- Darwish-Murad S, Plessier A, Hernandez-Guerra M, et al. A prospective study on 163 patients with Budd-Chiari syndrome: results from the European Network for Vascular Disorders of the Liver (EN-VIE). *J Hepatol* 2007;46: S4

- Valla DC. Hepatic vein thrombosis (Budd-Chiari syndrome). *Semin Liver Dis* 2002;22:5–14
- Okuda K. Inferior vena cava thrombosis at its hepatic portion (obliterative hepatocavopathy). *Semin Liver Dis* 2002;22:15–26
- Mehrotra G, Singh RP, Krishna A, Singh BK. Pyogenic liver abscess causing acute Budd-Chiari syndrome. *Ann Trop Paediatr* 1992;12:451–453
- Uddin W, Ramage JK, Portmann B, et al. Hepatic venous outflow obstruction in patients with polycystic liver disease: pathogenesis and treatment. *Gut* 1995;36:142–145
- Rangheard AS, Vilgrain V, Audet P, et al. Focal nodular hyperplasia inducing hepatic vein obstruction. *AJR Am J Roentgenol* 2002;179:759–762
- Kubo T, Shibata T, Itoh K, et al. Outcome of percutaneous transhepatic venoplasty for hepatic venous outflow obstruction after living donor liver transplantation. *Radiology* 2006;239:285–290
- Wang SL, Sze DY, Busque S, et al. Treatment of hepatic venous outflow obstruction after piggyback liver transplantation. *Radiology* 2005;236:352–359
- Balian A, Valla D, Naveau S, et al. Post-traumatic membranous obstruction of the inferior vena cava associated with a hypercoagulable state. *J Hepatol* 1998;28:723–726
- Markert DJ, Shanmuganathan K, Mirvis SE, Nakajima Y, Hayakawa M. Budd-Chiari syndrome resulting from intrahepatic IVC compression secondary to blunt hepatic trauma. *Clin Radiol* 1997;52:384–387
- Kim PN, Mitchell DG, Outwater EK. Budd-Chiari syndrome: hepatic venous obstruction by an elevated diaphragm. *Abdom Imaging* 1999;24:267–271
- Hirshberg B, Shouval D, Fibach E, Friedman G, Ben-Yehuda D. Flow cytometric analysis of autonomous growth of erythroid precursors in liquid culture detects occult polycythemia vera in the Budd-Chiari syndrome. *J Hepatol* 2000;32:574–578
- Janssen HL, Meinardi JR, Vleggaar FP, et al. Factor V Leiden mutation, prothrombin gene mutation, and deficiencies in coagulation inhibitors associated with Budd-Chiari syndrome and portal vein thrombosis: results of a case-control study. *Blood* 2000;96:2364–2368
- Mohanty D, Shetty S, Ghosh K, Pawar A, Abraham P. Hereditary thrombophilia as a cause of Budd-Chiari syndrome: a study from Western India. *Hepatology* 2001;34:666–670
- Deltenre P, Denninger MH, Hillaire S, et al. Factor V Leiden related Budd-Chiari syndrome. *Gut* 2001;48:264–268
- Lin GL, Xu PQ, Qi H, Lian JH, Zheng H, Dang XW. Relations of Budd-Chiari syndrome to prothrombin gene mutation. *Hepatobiliary Pancreat Dis Int* 2004;3:214–218
- Kumar SI, Kumar A, Srivastava S, Saraswat VA, Aggarwal R. Low frequency of factor V Leiden and prothrombin G20210A mutations in patients with hepatic venous outflow tract obstruction in northern India: a case-control study. *Indian J Gastroenterol* 2005;24:211–215
- Colak Y, Karasu Z, Oruc N, et al. Hyperhomocysteinemia and factor V Leiden mutation are associated with Budd-Chiari syndrome. *Eur J Gastroenterol Hepatol* 2006;18: 917–920
- Li XM, Wei YF, Hao HL, et al. Hyperhomocysteinemia and the MTHFR C677T mutation in Budd-Chiari syndrome. *Am J Hematol* 2002;71:11–14

25. Dayal S, Pati HP, Pande GK, Sharma MP, Saraya AK. Multilineage hemopoietic stem cell defects in Budd-Chiari syndrome. *J Hepatol* 1997;26:293-297
26. Bayraktar Y, Balkanci F, Kansu E, et al. Cavernous transformation of the portal vein: a common manifestation of Behcet's disease. *Am J Gastroenterol* 1995;90:1476-1479
27. Patel RK, Lea NC, Heneghan MA, et al. Prevalence of the activating JAK2 tyrosine kinase mutation V617F in the Budd-Chiari syndrome. *Gastroenterology* 2006;130:2031-2038
28. Primignani M, Barosi G, Bergamaschi G, et al. Role of the JAK2 mutation in the diagnosis of chronic myeloproliferative disorders in splanchnic vein thrombosis. *Hepatology* 2006;44:1528-1534
29. Kiladjian JJ, Cervantes F, Leebeek FW, et al. The impact of JAK2 and MPL mutations on diagnosis and prognosis of splanchnic vein thrombosis. A report on 241 cases. *Blood* 2008;111(10):4835-4836
30. Bayraktar Y, Balkanci F, Bayraktar M, Calguneri M. Budd-Chiari syndrome: a common complication of Behcet's disease. *Am J Gastroenterol* 1997;92:858-862
31. Zylberberg H, Valla D, Viguie F, Casadevall N. Budd-Chiari syndrome associated with 5q deletion and hyper-eosinophilia. *J Clin Gastroenterol* 1996;23:66-68
32. Young ID, Clark RN, Manley PN, Groll A, Simon JB. Response to steroids in Budd-Chiari syndrome caused by idiopathic granulomatous venulitis. *Gastroenterology* 1988;94:503-507
33. Rahhal RM, Pashankar DS, Bishop WP. Ulcerative colitis complicated by ischemic colitis and Budd-Chiari syndrome. *J Pediatr Gastroenterol Nutr* 2005;40:94-97
34. Dilawari JB, Bambery P, Chawla Y, et al. Hepatic outflow obstruction (Budd-Chiari syndrome). Experience with 177 patients and a review of the literature. *Medicine (Baltimore)* 1994;73:21-36
35. Khuroo MS, Datta DV. Budd-Chiari syndrome following pregnancy. Report of 16 cases, with roentgenologic, hemodynamic and histologic studies of the hepatic outflow tract. *Am J Med* 1980;68:113-121
36. Rautou PE, Angermayr B, Raffa S, et al. Maternal and fetal outcome in 27 women with Budd-Chiari syndrome and 41 pregnancies. *Hepatology* 2007;46:563A
37. Valla D, Le MG, Poynard T, Zucman N, Rueff B, Benhamou JP. Risk of hepatic vein thrombosis in relation to recent use of oral contraceptives. A case-control study. *Gastroenterology* 1986;90:807-811
38. Denninger MH, Chait Y, Casadevall N, et al. Cause of portal or hepatic venous thrombosis in adults: the role of multiple concurrent factors. *Hepatology* 2000;31:587-591
39. Parker RGF. Occlusion of the hepatic veins in man. *Medicine (Baltimore)* 1959;38:369-402
40. Hadengue A, Poliquin M, Vilgrain V, et al. The changing scene of hepatic vein thrombosis: recognition of asymptomatic cases. *Gastroenterology* 1994;106:1042-1047
41. Tanaka M, Wanless IR. Pathology of the liver in Budd-Chiari syndrome: portal vein thrombosis and the histogenesis of veno-centric cirrhosis, veno-portal cirrhosis, and large regenerative nodules. *Hepatology* 1998;27:488-496
42. Cazals-Hatem D, Vilgrain V, Genin P, et al. Arterial and portal circulation and parenchymal changes in Budd-Chiari syndrome: a study in 17 explanted livers. *Hepatology* 2003;37:510-519
43. Mahmoud AEA, Helmy AS, Billingham S, Elias E. Poor prognosis and limited therapeutic options in patients with Budd-Chiari syndrome and portal venous system thrombosis. *Eur J Gastroenterol Hepatol* 1997;9:485-489
44. Tavill AS, Wood EJ, Kreef L, Jones EA, Gregory M, Sherlock S. The Budd-Chiari syndrome: correlation between hepatic scintigraphy and the clinical, radiological, and pathological findings in nineteen cases of hepatic venous outflow obstruction. *Gastroenterology* 1975;68:509-518
45. Miller WJ, Federle MP, Straub WH, Davis PL. Budd-Chiari syndrome: imaging with pathologic correlation. *Abdom Imaging* 1993;18:329-335
46. Millener P, Grant EG, Rose S, et al. Color Doppler imaging findings in patients with Budd-Chiari syndrome: correlation with venographic findings. *AJR Am J Roentgenol* 1993;161:307-312
47. Chawla Y, Kumar S, Dhiman RK, Suri S, Dilawari JB. Duplex Doppler sonography in patients with Budd-Chiari syndrome. *J Gastroenterol Hepatol* 1999;14:904-907
48. Grant EG, Perrella R, Tessler FN, Lois J, Busuttill R. Budd-Chiari syndrome: the results of duplex and color Doppler imaging. *AJR Am J Roentgenol* 1989;152:377-381
49. Kane R, Eustace S. Diagnosis of Budd-Chiari syndrome: comparison between sonography and MR angiography. *Radiology* 1995;195:117-121
50. DeLeve LD, Shulman HM, McDonald GB. Toxic injury to hepatic sinusoids: sinusoidal obstruction syndrome (veno-occlusive disease). *Semin Liver Dis* 2002;22:27-42
51. Rector WG, Xu YH, Goldstein L, Peters RL, Reynolds TB. Membranous obstruction of the inferior vena cava in the United States. *Medicine (Baltimore)* 1985;64:134-143
52. Gupta S, Barter S, Phillips GW, Gibson RN, Hodgson HJ. Comparison of ultrasonography, computed tomography and 99mTc liver scan in diagnosis of Budd-Chiari syndrome. *Gut* 1987;28:242-247
53. Mathieu D, Kracht M, Zafrani E, Dhumeaux D, Vasile N. Budd-Chiari syndrome. Ferrucci J, Matthieu D, eds. *Advances in Hepatobiliary Radiology*. St Louis: C.V. Mosby Company; 1990:3-28
54. Menu Y, Alison D, Lorphelin JM, Valla D, Belghiti J, Nahum H. Budd-Chiari syndrome: US evaluation. *Radiology* 1985;157:761-764
55. Baert AL, Fevery J, Marchal G, et al. Early diagnosis of Budd-Chiari syndrome by computed tomography and ultrasonography: report of five cases. *Gastroenterology* 1983;84:587-595
56. Van Beers B, Pringot J, Trigaux JP, Dautrebande J, Mathurin P. Hepatic heterogeneity on CT in Budd-Chiari syndrome: correlation with regional disturbances in portal flow. *Gastrointest Radiol* 1988;13:61-66
57. Solano FX, Young E, Talamo TS, Dekker A. Constrictive pericarditis mimicking Budd-Chiari syndrome. *Am J Med* 1986;80:113-115
58. Shin SH, Chung YH, Suh DD, et al. Characteristic clinical features of hepatocellular carcinoma associated with Budd-Chiari syndrome: evidence of different carcinogenic process from hepatitis B virus-associated hepatocellular carcinoma. *Eur J Gastroenterol Hepatol* 2004;16:319-324
59. Havlioglu N, Brunt EM, Bacon BR. Budd-Chiari syndrome and hepatocellular carcinoma: a case report and review of the literature. *Am J Gastroenterol* 2003;98:201-204

60. Moucari R, Rautou PE, Cazals-Hatem D, et al. Hepatocellular carcinoma in Budd-Chiari syndrome: characteristics and risk factors. *Gut* 2008;57(6):828–835
61. Vons C, Smadja C, Franco D, Valla D, Rueff B, Benhamou JP. Successful pregnancy after Budd-Chiari syndrome. *Lancet* 1984;2:975
62. Landolfi R, Marchioli R, Kutti J, et al. Efficacy and safety of low-dose aspirin in polycythemia vera. *N Engl J Med* 2004;350:114–124
63. De Ledinghen V, Heresbach D, Fourdan O, et al. Anti-inflammatory drugs and variceal bleeding: a case-control study. *Gut* 1999;44:270–273
64. Bates SM, Ginsberg JS. Clinical practice. Treatment of deep-vein thrombosis. *N Engl J Med* 2004;351:268–277
65. Zeitoun G, Escolano S, Hadengue A, et al. Outcome of Budd-Chiari syndrome: a multivariate analysis of factors related to survival including surgical portosystemic shunting. *Hepatology* 1999;30:84–89
66. Murad SD, Valla DC, de Groen PC, et al. Determinants of survival and the effect of portosystemic shunting in patients with Budd-Chiari syndrome. *Hepatology* 2004;39:500–508
67. Plessier A, Sibert A, Consigny Y, et al. Aiming at minimal invasiveness as a therapeutic strategy for Budd-Chiari syndrome. *Hepatology* 2006;44:1308–1316
68. Eapen CE, Velissaris D, Heydtmann M, Gunson B, Olliff S, Elias E. Favourable medium term outcome following hepatic vein recanalisation and/or transjugular intrahepatic portosystemic shunt for Budd Chiari syndrome. *Gut* 2006;55:878–884
69. Campbell DA, Rolles K, Jamieson N, et al. Hepatic transplantation with perioperative and long term anticoagulation as treatment for Budd-Chiari syndrome. *Surg Gynecol Obstet* 1988;166:511–518
70. Halff G, Todo S, Tzakis AG, Gordon RD, Starzl TE. Liver transplantation for the Budd-Chiari syndrome. *Ann Surg* 1990;211:43–49
71. Zhang CQ, Fu LN, Xu L, et al. Long-term effect of stent placement in 115 patients with Budd-Chiari syndrome. *World J Gastroenterol* 2003;9:2587–2591
72. Plessier A, Sibert A, Consigny Y, et al. Aiming at minimal invasiveness as a therapeutic strategy for Budd-Chiari syndrome. *Hepatology* 2006;44(5):1308–1316
73. Barrault C, Plessier A, Valla D, Condat B. Non surgical treatment of Budd-Chiari syndrome: a review. *Gastroenterol Clin Biol* 2004;28:40–49
74. Sharma S, Teixeira A, Teixeira P, Elias E, Wilde J, Olliff SP. Pharmacological thrombolysis in Budd Chiari syndrome: a single centre experience and review of the literature. *J Hepatol* 2004;40:172–180
75. Hernandez-Guerra M, Lopez E, Bellot P, et al. Systemic hemodynamics, vasoactive systems, and plasma volume in patients with severe Budd-Chiari syndrome. *Hepatology* 2006;43:27–33
76. Valla D, Hadengue A, el Younsi M, et al. Hepatic venous outflow block caused by short-length hepatic vein stenoses. *Hepatology* 1997;25:814–819
77. Griffith JF, Mahmoud AE, Cooper S, Elias E, West RJ, Olliff SP. Radiological intervention in Budd-Chiari syndrome: techniques and outcome in 18 patients. *Clin Radiol* 1996;51:775–784
78. Martin LG, Henderson JM, Millikan WJ, Casarella WJ, Kaufman SL. Angioplasty for long-term treatment of patients with Budd-Chiari syndrome. *AJR Am J Roentgenol* 1990;154:1007–1010
79. Nunez O, de la Cruz G, Molina J, et al. Interventional radiology, angioplasty and TIPS in Budd-Chiari syndrome. *Gastroenterol Hepatol* 2003;26:461–464
80. Pelage JP, Denys A, Valla D, et al. Budd-Chiari syndrome due to prothrombotic disorder: mid-term patency and efficacy of endovascular stents. *Eur Radiol* 2003;13:286–293
81. Witte AM, Kool LJ, Veenendaal R, Lamers CB, van Hoek B. Hepatic vein stenting for Budd-Chiari syndrome. *Am J Gastroenterol* 1997;92:498–501
82. Qiao T, Liu CJ, Liu C, Chen K, Zhang XB, Zu MH. Interventional endovascular treatment for Budd-Chiari syndrome with long-term follow-up. *Swiss Med Wkly* 2005;135:318–326
83. Yamada R, Sato M, Kawabata M, Nakatsuka H, Nakamura K, Kobayashi N. Segmental obstruction of the hepatic inferior vena cava treated by transluminal angioplasty. *Radiology* 1983;149:91–96
84. Guan H. [Diagnosis and treatment of membranous obstruction of the inferior vena cava]. *Zhonghua Wai Ke Za Zhi* 1990;28:760–763783–764
85. Sato M, Yamada R, Tsuji K, et al. Percutaneous transluminal angioplasty in segmental obstruction of the hepatic inferior vena cava: long-term results. *Cardiovasc Intervent Radiol* 1990;13:189–192
86. Kohli V, Pande GK, Dev V, Reddy KS, Kaul U, Nundy S. Management of hepatic venous outflow obstruction. *Lancet* 1993;342:718–722
87. Yang XL, Cheng TO, Chen CR. Successful treatment by percutaneous balloon angioplasty of Budd-Chiari syndrome caused by membranous obstruction of inferior vena cava: 8-year follow-up study. *J Am Coll Cardiol* 1996;28:1720–1724
88. Tyagi S, Jain BL, Kumar N, Lahoti D, Arora R. Balloon dilatation of inferior vena cava stenosis in Budd-Chiari syndrome. *J Assoc Physicians India* 1996;44:378–380
89. Bilbao JL, Pueyo JC, Longo JM, et al. Interventional therapeutic techniques in Budd-Chiari syndrome. *Cardiovasc Intervent Radiol* 1997;20:112–119
90. De BK, Biswas PK, Sen S, et al. Management of the Budd-Chiari syndrome by balloon cavoplasty. *Indian J Gastroenterol* 2001;20:151–154
91. Wu T, Wang L, Xiao Q, et al. Percutaneous balloon angioplasty of inferior vena cava in Budd-Chiari syndrome-R1. *Int J Cardiol* 2002;83:175–178
92. Mishra TK, Routray SN, Behera M, Patnaik UK, Satapathy C. Percutaneous balloon angioplasty of membranous obstruction of the inferior vena cava. *Indian Heart J* 2003;55:362–364
93. Xu K, Feng B, Zhong H, et al. Clinical application of interventional techniques in the treatment of Budd-Chiari syndrome. *Chin Med J (Engl)* 2003;116:609–615
94. Xiaoming Z, Zhonggao W. Interventional or semi-interventional treatment for Budd-Chiari syndrome. *Chin Med Sci J* 2003;18:111–115
95. Khuroo MS, Al-Suhabani H, Al-Sebayel M, et al. Budd-Chiari syndrome: long-term effect on outcome with transjugular intrahepatic portosystemic shunt. *J Gastroenterol Hepatol* 2005;20:1494–1502
96. Lee BB, Villavicencio L, Kim YW, et al. Primary Budd-Chiari syndrome: outcome of endovascular management for

- suprahepatic venous obstruction. *J Vasc Surg* 2006;43:101–108
97. Furui S, Sawada S, Irie T, et al. Hepatic inferior vena cava obstruction: treatment of two types with Gianturco expandable metallic stents. *Radiology* 1990;176:665–670
  98. Langlet P, Valla D. Is surgical portosystemic shunt the treatment of choice in Budd-Chiari syndrome? *Acta Gastroenterol Belg* 2002;65:155–160
  99. Panis Y, Belghiti J, Valla D, Benhamou JP, Fekete F. Portosystemic shunt in Budd-Chiari syndrome: long-term survival and factors affecting shunt patency in 25 patients in Western countries. *Surgery* 1994;115:276–281
  100. Hemming AW, Langer B, Greig P, Taylor BR, Adams R, Heathcote EJ. Treatment of Budd-Chiari syndrome with portosystemic shunt or liver transplantation. *Am J Surg* 1996;171:176–180; discussion 180–171
  101. Tang TJ, Batts KP, de Groen PC, et al. The prognostic value of histology in the assessment of patients with Budd-Chiari syndrome. *J Hepatol* 2001;35:338–343
  102. Langlet P, Escolano S, Valla D, et al. Clinicopathological forms and prognostic index in Budd-Chiari syndrome. *J Hepatol* 2003;39:496–501
  103. Bachet JB, Condat B, Hagege H, et al. Long term portosystemic shunt patency as a determinant of outcome in Budd-Chiari syndrome. *J Hepatol* 2007;46(1):60–68
  104. Feng LS, Peng QP, Li K, et al. Management of severe Budd-Chiari syndrome: report of 147 cases. *Hepatobiliary Pancreat Dis Int* 2004;3:522–525
  105. Savader SJ, Venbrux AC, Klein AS, Osterman FA. Percutaneous intervention in portosystemic shunts in Budd-Chiari syndrome. *J Vasc Interv Radiol* 1991;2:489–495
  106. Orloff MJ, Daily PO, Orloff SL, Girard B, Orloff MS. A 27-year experience with surgical treatment of Budd-Chiari syndrome. *Ann Surg* 2000;232:340–352
  107. Bismuth H, Sherlock DJ. Portasystemic shunting versus liver transplantation for the Budd-Chiari syndrome. *Ann Surg* 1991;214:581–589
  108. Orloff LA, Orloff MJ. Budd-Chiari syndrome caused by Behcet's disease: treatment by side-to-side portacaval shunt. *J Am Coll Surg* 1999;188:396–407
  109. Ganger DR, Klapman JB, McDonald V, et al. Transjugular intrahepatic portosystemic shunt (TIPS) for Budd-Chiari syndrome or portal vein thrombosis: review of indications and problems. *Am J Gastroenterol* 1999;94:603–608
  110. Ryu RK, Durham JD, Krysl J, et al. Role of TIPS as a bridge to hepatic transplantation in Budd-Chiari syndrome. *J Vasc Interv Radiol* 1999;10:799–805
  111. Slakey DP, Klein AS, Venbrux AC, Cameron JL. Budd-Chiari syndrome: current management options. *Ann Surg* 2001;233:522–527
  112. Cejna M, Peck-Radosavljevic M, Schoder M, et al. Repeat interventions for maintenance of transjugular intrahepatic portosystemic shunt function in patients with Budd-Chiari syndrome. *J Vasc Interv Radiol* 2002;13:193–199
  113. Perello A, Garcia-Pagan JC, Gilibert R, et al. TIPS is a useful long-term derivative therapy for patients with Budd-Chiari syndrome uncontrolled by medical therapy. *Hepatology* 2002;35:132–139
  114. Blokzijl H, de Knegt RJ. Long-term effect of treatment of acute Budd-Chiari syndrome with a transjugular intrahepatic portosystemic shunt. *Hepatology* 2002;35:1551–1552
  115. Mancuso A, Fung K, Mela M, et al. TIPS for acute and chronic Budd-Chiari syndrome: a single-centre experience. *J Hepatol* 2003;38:751–754
  116. Kavanagh PM, Roberts J, Gibney R, Malone D, Hegarty J, McCormick PA. Acute Budd-Chiari syndrome with liver failure: the experience of a policy of initial interventional radiological treatment using transjugular intrahepatic portosystemic shunt. *J Gastroenterol Hepatol* 2004;19:1135–1139
  117. Attwell A, Ludkowski M, Nash R, Kugelmas M. Treatment of Budd-Chiari syndrome in a liver transplant unit, the role of transjugular intrahepatic porto-systemic shunt and liver transplantation. *Aliment Pharmacol Ther* 2004;20:867–873
  118. Rossle M, Olschewski M, Siegerstetter V, Berger E, Kurz K, Grandt D. The Budd-Chiari syndrome: outcome after treatment with the transjugular intrahepatic portosystemic shunt. *Surgery* 2004;135:394–403
  119. Safka V, Hulek P, Krajina A, et al. Budd-Chiari syndrome and TIPS—twelve years' experience. *Cas Lek Cesk* 2005; 144(Suppl 3):38–42
  120. Molmenti EP, Segev DL, Arepally A, et al. The utility of TIPS in the management of Budd-Chiari syndrome. *Ann Surg* 2005;241:978–981; discussion 982–973
  121. Hernandez-Guerra M, Turnes J, Rubinstein P, et al. PTFE-covered stents improve TIPS patency in Budd-Chiari syndrome. *Hepatology* 2004;40:1197–1202
  122. Mentha G, Giostra E, Majno PE, et al. Liver transplantation for Budd-Chiari syndrome: A European study on 248 patients from 51 centres. *J Hepatol* 2006;44:520–528
  123. Shaked A, Goldstein RM, Klintmalm GB, Drazan K, Husberg B, Busuttil RW. Portosystemic shunt versus orthotopic liver transplantation for the Budd-Chiari syndrome. *Surg Gynecol Obstet* 1992;174:453–459
  124. Ringe B, Lang H, Oldhafer KJ, et al. Which is the best surgery for Budd-Chiari syndrome: venous decompression or liver transplantation? A single-center experience with 50 patients. *Hepatology* 1995;21:1337–1344
  125. Henderson JM, Warren WD, Millikan WJ, et al. Surgical options, hematologic evaluation, and pathologic changes in Budd-Chiari syndrome. *Am J Surg* 1990;159:41–48; discussion 48–50
  126. Malkowski P, Michalowicz B, Pawlak J, et al. Surgical and interventional radiological treatment of Budd-Chiari syndrome: report of nine cases. *Hepatogastroenterology* 2003;50: 2049–2051
  127. Jamieson NV, Williams R, Calne RY. Liver transplantation for Budd-Chiari syndrome, 1976–1990. *Ann Chir* 1991;45: 362–365
  128. Srinivasan P, Rela M, Prachalias A, et al. Liver transplantation for Budd-Chiari syndrome. *Transplantation* 2002; 73:973–977
  129. Segev DL, Nguyen GC, Locke JE, et al. Twenty years of liver transplantation for Budd-Chiari syndrome: a national registry analysis. *Liver Transpl* 2007;13:1285–1294
  130. Melear JM, Goldstein RM, Levy MF, et al. Hematologic aspects of liver transplantation for Budd-Chiari syndrome with special reference to myeloproliferative disorders. *Transplantation* 2002;74:1090–1095
  131. Valla DC. Prognosis in Budd Chiari syndrome after re-establishing hepatic venous drainage. *Gut* 2006;55:761–763
  132. Min AD, Atillasoy EO, Schwartz ME, Thiim M, Miller CM, Bodenheimer HC. Reassessing the role of medical

- therapy in the management of hepatic vein thrombosis. *Liver Transpl Surg* 1997;3:423-429
133. Murad SD, Valla DC, de Groen PC, et al. Pathogenesis and treatment of Budd-Chiari syndrome combined with portal vein thrombosis. *Am J Gastroenterol* 2006;101:83-90
134. Chait Y, Condat B, Cazals-Hatem D, et al. Relevance of the criteria commonly used to diagnose myeloproliferative disorder in patients with splanchnic vein thrombosis. *Br J Haematol* 2005;129:553-560
135. Gentil-Kocher S, Bernard O, Brunelle F, et al. Budd-Chiari syndrome in children: report of 22 cases. *J Pediatr* 1988;113:30-38
136. Boudhina T, Ghram N, Ben Becher S, et al. Budd-Chiari syndrome in children. Apropos of 7 cases. *Arch Fr Pediatr* 1991;48:243-248
137. Odell JA, Rode H, Millar AJ, Hoffman HD. Surgical repair in children with the Budd-Chiari syndrome. *J Thorac Cardiovasc Surg* 1995;110:916-923
138. Senzolo M, Tibbals J, Cholongitas E, Triantos CK, Burroughs AK, Patch D. Transjugular intrahepatic porto-systemic shunt for portal vein thrombosis with and without cavernous transformation. *Aliment Pharmacol Ther* 2006;23:767-775