

# Collagenous colitis

**Author: Doctor Fernando Fernández-Bañares<sup>1</sup>,**

**Creation Date: July 2003**

**Update: February 2005**

**Scientific editor: Professor Jean-Alain Chayvialle**

<sup>1</sup>Department of Gastroenterology, Hospital Universitari Mutua Terrassa, Plaza Dr Robert nº 5, 08221 Terrassa (Barcelona), Spain. [digestiu@mutuaterrassa.es](mailto:digestiu@mutuaterrassa.es)

[Abstract](#)

[Key-words](#)

[Disease name and synonyms](#)

[Diagnosis criteria/definition](#)

[Differential diagnosis](#)

[Incidence](#)

[Clinical description](#)

[Management including treatment](#)

[Etiology](#)

[Diagnostic methods](#)

[Unresolved questions](#)

[References](#)

## Abstract

*Collagenous colitis is characterized by chronic watery diarrhea, normal radiological and endoscopic appearances, and microscopic abnormalities in the colon. The specific histopathological feature is the presence of a subepithelial collagen band (10  $\mu$ m or more) adjacent to the basal membrane, together with epithelial lymphocyte infiltration and chronic inflammation in lamina propria. A mean annual incidence of 0.6 to 6.1 per 100,000 inhabitants has been described, with a peak incidence in older women. The overall prognosis of the disease is good because cases with life-threatening diarrhea are extremely rare, and diarrhea subsides in almost all patients either spontaneously (near 20%) or with adequate therapy. Recent randomised placebo-controlled trials suggest that budesonide is an effective treatment for collagenous colitis inducing short-term clinical response in 57 to 87% of patients. However, relapse usually occurs early after stopping the drug, and thus maintenance therapy with low doses of budesonide is often required. Uncontrolled studies suggest that either mesalazine, cholestyramine, or bismuth subsalicylate are also effective. The etiology and pathogenesis of collagenous colitis are unknown. A mechanism based on genetic-predisposition, with some features of autoimmunity, initiated by a noxious agent(s) in the fecal stream, which would induce dysfunction of signal transmission between surface epithelium and subepithelial myofibroblasts generating abnormalities in collagen synthesis and/or degradation has been evoked.*

## Key-words

Collagenous colitis, microscopic colitis, chronic watery diarrhea, inflammatory bowel disease.

## Disease name and synonyms

Collagenous colitis is a disease included into the spectrum of microscopic colitis syndrome. Other diseases included are lymphocytic colitis and microscopic colitis with giant cells. Patients with similar clinical characteristics but with colonic

biopsies disclosing only chronic inflammation in lamina propria are referred to as microscopic colitis NOS (not otherwise specified) until we know more about classification and etiology (1).

### Diagnosis criteria/definition

Collagenous colitis is a disease characterized by chronic watery diarrhea, normal radiological and endoscopic appearances, and microscopic abnormalities in the colon. The specific histopathological feature characterizing the disease is the presence of a subepithelial collagen band (10 µm or more) adjacent to the basal membrane.

### Differential diagnosis

Collagenous colitis is characterized by chronic watery diarrhea with normal blood analysis, negative stool culture and negative stool parasites and ova. Since the radiological and endoscopic appearances are also normal, the following diseases, which can have similar features, must be ruled out:

- Functional chronic diarrhea.
- Diarrhea-predominant irritable bowel syndrome.
- Lymphocytic colitis.
- Other forms of [microscopic colitis](#).
- Some forms of mild [celiac disease](#).
- Some forms of mild [ulcerative colitis](#) (with only microscopic damage –minimal change colitis-) (1).
- Some infectious colitis (*i.e.*, CMV colitis, diarrhea in HIV patients).
- Iatrogenic colitis

### Incidence

The incidence of collagenous colitis was estimated in several population-based studies (2-5). The reported mean annual incidence ranges from 0.8 to 6.1 per 100,000 inhabitants. Peak incidence was observed in older women (up to 26.9 per 100,000 in women aged 60-69 years in Sweden studies).

On the other hand, microscopic colitis was diagnosed at a rate of 10 per 100 normal-looking colonoscopies performed in patients with chronic watery diarrhea, and of almost 20% of those older than 70 years.

### Clinical description

Collagenous colitis is characterized by chronic or intermittent watery diarrhea, which can range from relatively mild and self-limited to severe and medically refractory, requiring surgery. In a recent study, a specific program was undertaken to prospectively diagnose all patients with microscopic colitis from those referred for a full colonoscopy because of recurrent or chronic diarrhea (6). This policy implies that patients with mild forms of the disease were detected, and thus description of clinical presentation and response to therapy better reflect the full spectrum of the disease than previous studies. Eighty-one patients (37 patients with collagenous colitis and 44 with lymphocytic

colitis) were included during a nine years period of time. Collagenous colitis was more common in women (male:female ratio 1:6.4). The mean age at onset of symptoms was 57. Median duration of diarrhea before diagnosis was 24 months. Affected patients usually produce between four and nine watery stools per day, which can include nocturnal stools. In addition to chronic watery diarrhea, meteorism, abdominal pain, urgency, and fecal incontinence were frequently seen. Slight weight loss was reported by 50% of patients. No patients with severe and medically refractory diarrhea were observed. In this context, and if colonic mucosal pathology is overlooked, most patients with collagenous colitis would be diagnosed with functional chronic diarrhea or with diarrhea-predominant irritable bowel syndrome.

A significantly higher number of patients with associated diseases of possible autoimmune origin was noted in microscopic colitis as compared with a functional diarrhea control group (28% versus 11%), mainly thyroid disorders and different forms of arthritis (6). On the other hand, it has been described that 0 to 30% of patients with microscopic colitis have associated [celiac disease](#) (7-11). Other associated autoimmune diseases are: [Sjögren's syndrome](#), [scleroderma](#), Raynaud's disease, recurrent iritis, [giant cell arteritis](#), [systemic lupus erythematosus](#), diabetes mellitus, [sarcoidosis](#), psoriasis, [myasthenia gravis](#), [Crohn's disease](#), [ulcerative colitis](#), etc (6-8).

In every patient, it is important to make a correct history of recent drug consumption. There are some medications with a suggested role in the pathogenesis of microscopic colitis or acting as triggers of diarrhea (NSAID, ranitidine, lansoprazole, venotonic drugs, ticlopidine, flutamide) (12). In these patients, symptoms may resolve quickly on drug discontinuation without requiring any anti-inflammatory drug.

The overall prognosis of the disease is good because patients with life-threatening diarrhea are extremely rare, and diarrhea subsides in almost all patients either spontaneously (near 20%) or with adequate therapy (6-8). In addition, after achieving clinical remission, only 25 to 30% of patients may have diarrhea relapse during follow-up, with good response to the initial therapy (6). Some require maintenance therapy. On the other hand, microscopic colitis has not been associated with increased mortality and does not appear to have a malignant potential.

### Management including treatment

Initial therapy consists of stopping NSAID and other possible causative drugs, and alleviating the primary symptom, diarrhea. Some patients improve spontaneously or with the use of non-specific antidiarrheal medications such as

loperamide or bulking agents. Most require specific treatment. Recent randomised placebo-controlled trials suggest that budesonide (9 mg daily) is an effective treatment for collagenous colitis inducing short-term clinical response in 57 to 87% of patients (13-15), and improving the deteriorated quality of life of these patients (16). Response to budesonide has been reported even in patients refractory to systemic steroids (17). After achieving clinical remission, clinical relapse occurs in 60% of patients within 3 months after cessation of therapy (median 2 weeks) (18). In such cases, maintenance therapy with low doses of budesonide (3 mg daily) would be effective to remain symptom free. In contrast to classic steroids, the long-term use of budesonide is associated with minimal or no impact on the adrenal function (19). Previous uncontrolled studies (6,7,20) have suggested that prednisone (1 mg/kg/day) is also highly effective to stop diarrhea (up to 80%), but relapse usually occurs early after tapering and the dose required to maintain remission is often unacceptable high, more than 20 mg/day.

There are no randomised controlled trials evaluating the effect of the other medications usually administered to patients with collagenous colitis and therapy remains largely empirical and based on the suggestions of recent large uncontrolled series (6,7,20). Response to salicylates, mainly in the form of mesalazine (1 g t.i.d.), is around 40-60%. In a review of the medical treatment of collagenous colitis, the response to mesalazine was 92% (21). However, these data were based on multiple small series and case reports and, thus, have scarce validity. On the other hand, cholestyramine (2 to 12 g daily) has been highly effective in patients with concomitant bile acid malabsorption, which is observed in 30 to 44% of patients with collagenous colitis (22,23), with a clinical remission rate of around 80%. Results of the two studies assessing the efficacy of this drug in patients with normal bile acid absorption are controversial with responses of 20% and 67%, respectively (22,23). There is a need for placebo-controlled trials in this setting.

Another promising therapy is bismuth subsalicylate (two or three 262 mg chewable tablets t.i.d.). Results of an open-label study and preliminary results of a placebo-controlled trial suggest that this agent is beneficial in many patients (24,25). These initial studies reported that most patients had complete resolution of diarrhea; however, other authors have reported that most patients express only a partial response (20).

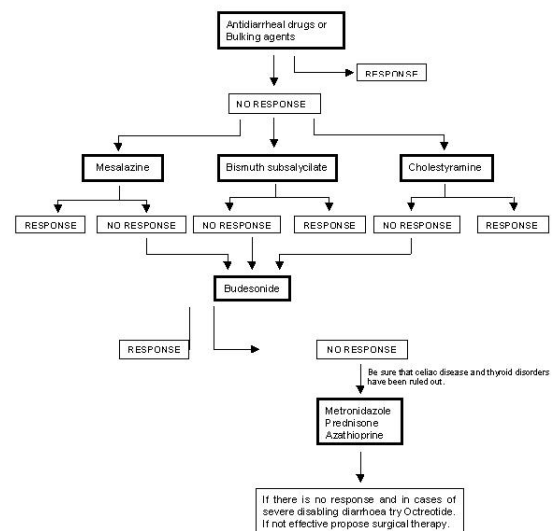
A number of other regimens have been effective in small case series in patients with diarrhea resistant to corticosteroids. These include

metronidazole (500 mg b.i.d.) (7), and azathioprine (2mg/kg/day) (26,27), and for severe symptomatic diarrhea, octreotide (50 to 100 mg every eight hours, S.C.) (28). Additional causes of diarrhea that have to be excluded in the case of unresponsive diarrhea are celiac disease and hyperthyroidism.

Patients are rarely refractory to medical therapy. In cases with severe disabling diarrhea, surgical therapy (diverting ileostomy or total proctocolectomy with permanent ileostomy) has been performed (29-31).

An approach to treatment of collagenous colitis in clinical practice is suggested in **Figure 1**. Deciding between mesalazine, bismuth and cholestyramine will depend on drug availability and preferences of the physician in charge. If there is concomitant bile acid malabsorption, cholestyramine seems to be more efficient than the other two drugs, mainly when using flavoured sachets that have improved the taste and texture of this agent, favouring compliance. However further controlled trials comparing these medications are needed. Most patients will respond to this treatment schedule but it is not clear how long treatment must be sustained for. In general, when an agent is found to control diarrhea, it should be maintained for 3 to 6 months, after which an attempt at tapering may be considered. For those patients with diarrhea recurrence, longer maintenance therapy should be used.

**Figure 1. Algorithm of collagenous colitis treatment**



## Etiology

The etiology and pathogenesis of collagenous colitis are unknown. Several hypotheses have been raised. As in other inflammatory bowel diseases an underlying immunopathologic process of autoimmune origin has been suggested. This hypothesis is based on the frequent association with other autoimmune diseases, the female preponderance, the lymphocyte infiltration at the site of inflammation, and the responsiveness to steroid therapy. However, the specific antibody in collagenous colitis is still to be found (32-35).

On the other hand, the lymphocyte infiltration in the surface epithelium has suggested that the inflammation could be initiated by a noxious agent(s) in the fecal stream (36). In this sense, symptoms and histological damage resolve with a diverting ileostomy (29,30). However, there are no data about the nature of the offending antigen.

There are data suggesting that pericryptal subepithelial myofibroblasts have an abnormal appearance and express markers of activity (alpha-smooth muscle actin) in collagenous colitis, but not in lymphocytic colitis (37,38). These cells are located at the interface between the epithelium and lamina propria in mucosal tissues. They are responsible for the normal production and deposition of collagen in the basement membrane, but also may modulate information transfer between these tissue compartments and play a pivotal role in mucosal immunophysiology (39-43). Abnormalities in collagen synthesis and/or degradation and dysfunction of signal transmission could be crucial determinants in the pathogenesis of collagenous colitis (44-46). To critically test this hypothesis, the biological functions of the pericryptal subepithelial myofibroblasts at the cellular and molecular levels must be elucidated. Association of collagenous colitis with HLA-DQ2, similar to the pattern seen in celiac disease, has been suggested by one group (10), but not corroborated by other authors who found an association of these HLA genes with lymphocytic colitis but not with collagenous colitis (11).

All these hypothesis may be integrated. In this sense, the possibility of a process with genetic-predisposition, with some features of autoimmunity, initiated by a noxious agent(s) in the fecal stream, which would induce dysfunction of signal transmission between surface epithelium and subepithelial myofibroblasts generating abnormalities in collagen synthesis and/or degradation has been raised.

## Diagnostic methods

The diagnosis of collagenous colitis is based on a compatible clinical picture and well-established

objective histological criteria. Clinical criteria included chronic or recurrent watery diarrhea of at least 1 month duration, and grossly normal colonoscopy. Firm diagnosis of collagenous colitis can only be established after multiple colon biopsies are performed in patients with normal-looking colonic mucosa. The reliability of left-sided colon biopsies for making the diagnosis of microscopic colitis is somewhat controversial. Some studies have suggested that rectal biopsies can miss the diagnosis in 11-40% (3,47), others have reported that the transverse colon provides the most diagnostic biopsies (48) and, finally, others report that multiple left-sided biopsies are very reliable, missing 0-5% of cases (3,49). In this sense, flexible sigmoidoscopy with multiple biopsies from the descending and sigmoid colon may be reasonably accurate to obtain a conclusive diagnosis. However, if full colonoscopy is performed or if left-sided biopsies are non-diagnostic and clinical suspicion remains high, proximal biopsies should be considered.

The histological criteria are (1,3,50):

- 1) Presence of an abnormal surface subepithelial collagen layer with a thickness >10 mm (normal 5-7 mm), which entraps superficial capillaries and with an irregular lacy appearance of the lower edge of the basement membrane;
- 2) Increased chronic inflammatory infiltrate (plasma cells, eosinophils and lymphocytes) in the lamina propria;
- 3) Increased number of intra-epithelial lymphocytes (IEL) (normal <7 per 100 epithelial cells);
- 4) Damage of surface epithelium, with flattening of epithelial cells and/or epithelial loss and detachment, and minimal crypt architecture distortion.

It is important to note that neutrophils, though not dominating the histological picture, may be present in collagenous colitis. Even the presence of focal acute cryptitis does not rule out collagenous colitis if the other histological and clinical features support the diagnosis (51).

A number of IEL higher than 20 lymphocytes per 100 epithelial cells in the absence of a thickened subepithelial collagen layer (<10 mm) are the histological criteria necessary to diagnose lymphocytic colitis (1,3,50). The discontinuous nature of the thickened subepithelial collagen band may lead to problems of interpretation. In this sense, several authors have showed that immunohistological labelling for tenascin, an extracellular matrix glycoprotein that is expressed during stromal remodelling, enables a more precise measurement of the thickness of the collagen deposits than conventional staining (38,52).

### Unresolved questions

The etiology and pathogenesis of the disease remain obscure. The existence of a fecal offending antigen as initiating agent of the disease has to be further studied. The role of pericryptal subepithelial myofibroblasts has to be elucidated.

Further controlled trials evaluating the efficacy of mesalamine, cholestyramine and bismuth among them and as compared to budesonide to induce long-term histological and clinical remission will be needed. The role of budesonide for maintenance therapy should be determined.

### References

- Warren BF, Edwards CM, Travis SPL. 'Microscopic colitis': classification and terminology. *Histopathology* 2002; 40:374-6.
- Bohr J, Tysk C, Eriksson S, *et al.* Collagenous colitis in Örebro, Sweden, an epidemiological study 1984-1993. *Gut* 1995; 37:394-7.
- Fernández-Bañares F, Salas A, Forné M, Esteve M, Espinós J, Viver JM. Incidence of collagenous and lymphocytic colitis: a five-year population based study. *Am J Gastroenterol* 1999; 94: 418-23.
- Olesen M, Eriksson S, Bohr J, Järnerot G, Tysk C. Microscopic colitis: a common diarrheal disease. An epidemiological study in Örebro, Sweden, 1993-1998. *Gut* 2004; 53:346-350.
- Agnarsdottir M, Gunnlaugsson O, Orvar KB, *et al.* Collagenous and lymphocytic colitis in Iceland. *Dig Dis Sci* 2002; 47:1122-8.
- Fernandez-Bañares F, Salas A, Esteve M, Espinós JC, Forné M, Viver JM. Collagenous and lymphocytic colitis: evaluation of clinical and histological features, response to treatment, and long-term follow up. *Am J Gastroenterol* 2003; 98:340-7.
- Bohr J, Tysk C, Eriksson S, Abrahamsson H, Järnerot G. Collagenous colitis: a retrospective study of clinical presentation and treatment in 163 patients. *Gut* 1996; 39:846-51.
- Baert F, Wouters K, D'Haens G, *et al.* Lymphocytic colitis: a distinct clinical entity? A clinicopathological confrontation of lymphocytic and collagenous colitis. *Gut* 1999; 45:375-81.
- Schneider S, Rampal A, Hebuterne X, Rampal P. Les colites microscopiques. *Gastroenterol Clin Biol* 1998; 22:431-41.
- Fine KD, Do K, Schulte K *et al.* High prevalence of celiac-sprue-like HLA-DQ genes and enteropathy in patients with the microscopic colitis syndrome. *Am J Gastroenterol* 2000; 95:1974-82.
- Fernández-Bañares F, Esteve M, Farré C, Salas A, Alsina M, Espinós J, *et al.* Predisposing genes of celiac disease HLA-DQ2 and HLA-DQ8 and associated enteropathy in microscopic colitis. *Gastroenterol Hepatol* 2005;28:A32.
- Cappell MS. Colonic toxicity of administered drugs and chemicals. *Am J Gastroenterol* 2004; 99:1175-90.
- Miehlke S, Heymer P, Bethke B, Baestlein E, Meier E, Bartram HP, *et al.* Budesonide treatment for collagenous colitis: A randomized, double-blind, placebo-controlled, multicenter trial. *Gastroenterology* 2002; 123:978-84.
- Baert F, Schmit A, D'Haens G, Dedeurwaerdere F, Louis E, Cabooter M, *et al.* Budesonide in collagenous colitis: A double-blind placebo-controlled trial with histologic follow-up. *Gastroenterology* 2002; 122:20-5.
- Bonderup OK, Hansen JB, Birket-Smith L, Vestergaard V, Teglbjaerg PS, Fallingborg J. Budesonide treatment of collagenous colitis: a randomised, double blind, placebo controlled trial with morphometric analysis. *Gut* 2003; 52:248-51.
- Madisch A, Heymer P, Voss C, Wiggingshaus B, Bastlein E, Bayerdorffer E *et al.* Oral budesonide therapy improves quality of life in patients with collagenous colitis. *Int J Colorectal Dis* 2004; Nov 11 (online).
- Lanyi B, Dries V, Dienes HP, Krus W. Therapy of prednisone-refractory collagenous colitis with budesonide. *Int J Colorect Dis* 1999; 14:58-61.
- Miehlke S, Madisch A, Voss C, Kuhlisch E, Morgner A, Heymer P *et al.* Long-term follow-up and predictive factors for clinical relapse in patients with collagenous colitis after induction of remission with budesonide capsules (abstract). *Gastroenterology* 2004; 126:A465.
- Greenberg GR, Feagan BG, Martin F, Sutherland LR, Thomson ABR, Williams CN, *et al.* Oral budesonide as maintenance treatment for Crohn's disease: A placebo-controlled, dose-ranging study. *Gastroenterology* 1996; 110:45-51.
- Pardi DS, Smyrk TC, Tremaine WJ, Sandborn WJ. Microscopic colitis: a review. *Am J Gastroenterol* 2002; 97:794-802.
- Zins BJ, Sandborn WJ, Tremaine WJ. Collagenous and lymphocytic colitis: Subject review and therapeutic alternatives. *Am J Gastroenterol* 1995; 90:1394-1400.
- Fernández-Bañares F, Esteve M, Salas A, Forné M, Espinós JC, Martín-Comín J, Viver JM. Bile acid malabsorption in microscopic colitis and in previously unexplained chronic diarrhea. *Dig Dis Sci* 2001; 46:2231-8.
- Ung KA, Gillberg R, Kilander A, Abrahamsson H. Role of bile acids and bile acid binding agents in patients with collagenous colitis. *Gut* 2000; 46:170-5.
- Fine KD, Lee EL. Efficacy of open-label bismuth subsalicylate for the treatment of microscopic colitis. *Gastroenterology* 1998; 114:29-36.

25. Fine KD, Ogunji F, Lee EL, Lafon G, Tanzi M. Randomized, double-blind, placebo-controlled trial of bismuth subsalicylate for microscopic colitis (abstract). *Gastroenterology* 1999; 116:A880.
26. Pardi DS, Loftus EV, Tremaine WJ, Sandborn WJ. Treatment of refractory microscopic colitis with azathioprine and 6-mercaptopurine. *Gastroenterology* 2001; 120:1483-4.
27. Vennamaneni SR, Bonner GF. Use of azathioprine or 6-mercaptopurine for treatment of steroid-dependent lymphocytic and collagenous colitis. *Am J Gastroenterol* 2001; 96:2798-9.
28. Fisher NC, Tutt A, Sim E, *et al.* Collagenous colitis responsive to octreotide therapy. *J Clin Gastroenterol* 1996; 23:300-1.
29. Jarnerot G, Tysk C, Bohr J, *et al.* Collagenous colitis and fecal stream diversion. *Gastroenterology* 1995; 109:449-55.
30. Williams RA, Gelfand DV. Total proctocolectomy and ileal pouch anal anastomosis to successfully treat a patient with collagenous colitis (letter). *Am J Gastroenterol* 2000; 95:2147.
31. Riaz AA, Pitt J, Stirling RW, *et al.* Restorative proctocolectomy for collagenous colitis. *J R Soc Med* 2000; 93:261.
32. Snook J. Are the inflammatory bowel diseases autoimmune disorders? *Gut* 1990; 31:961-3.
33. Bohr J, Tysk C, Yang P *et al.* Autoantibodies and immunoglobulins in collagenous colitis. *Gut* 1996; 39:73-6.
34. Freeman HJ. Perinuclear antineutrophil cytoplasmic antibodies in collagenous or lymphocytic colitis with or without celiac disease. *Can J Gastroenterol* 1997; 11:417-21.
35. Duerr RH, Targan SR, Landers CJ, *et al.* Anti-neutrophil cytoplasmic antibodies in ulcerative colitis. Comparison with other colitides/diarrheal illnesses. *Gastroenterology* 1991; 100:1590-6.
36. Bohr J. A review of collagenous colitis. *Scand J Gastroenterol* 1998; 33:2-9.
37. Hwang WS, Kelly JK, Shaffer EA, Hershfield NB. Collagenous colitis: A disease of pericryptal fibroblast sheath? *J Pathol* 1986; 149:33-40.
38. Salas A, Fernández-Bañares F, Casalots J, González C, Tarroch X, Forcada P, González G. Subepithelial myofibroblasts and tenascin expression in microscopic colitis. *Histopathology* 2003; 43:48-54.
39. Powell DW, Mifflin RC, Valentich JD, Crowe SE, Saada JI, West AB. Myofibroblasts. II. Intestinal subepithelial myofibroblasts. *Am J Physiol* 1999; 277:C183-C201.
40. Valentich JD, Powell DW. Intestinal subepithelial myofibroblasts and mucosal immunophysiology. *Curr Op Gastroenterol* 1994; 10:645-51.
41. Fristch C, Simon-Assmann P, Kedinger M, Evans GS. Cytokines modulate fibroblast phenotype and epithelial-stroma interactions in rat intestine. *Gastroenterology* 1997; 112:826-38.
42. Roberts AI, Nadler SC, Ebert EC. Mesenchymal cells stimulate human intestinal intrapithelial lymphocytes. *Gastroenterology* 1997; 113:144-50.
43. Jobson TM, Billington CK, Hall IP. Regulation of proliferation of human colonic subepithelial myofibroblasts by mediators important in intestinal inflammation. *J Clin Invest* 1998; 101:2650-7.
44. Günther U, Schuppan D, Bauer M, Matthes H, Stallmach A, Schmitt-Gräff A, *et al.* Fibrogenesis and fibrolysis in collagenous colitis. Patterns of procollagen types I and IV, matrix-metalloproteinase-1 and -13, and TIMP-1 gene expression. *Am J Pathol* 1999; 155:493-503.
45. Aigner T, Neureiter D, Müller S, Küspert G, Belke J, Kirchner T. Extracellular matrix composition and gene expression in collagenous colitis. *Gastroenterology* 1997; 113:136-43.
46. Griga T, Brasch F, Pfisterer O, Mueller KM, Tromm A, Schmiegel W. Collagenous colitis: Implications for the role of vascular endothelial growth factor in repair mechanisms. *Gastroenterology* 2003; 124 (Suppl1):A142.
47. Carpenter H, Tremaine W, Batts K, Czaja A. Sequential histological evaluations in collagenous colitis. *Dig Dis Sci* 1992; 37:1903-9.
48. Offner FA, Jao RV, Lewin KS, *et al.* Collagenous colitis: A study of the distribution of morphological abnormalities and their histological detection. *Hum Pathol* 1999; 30:451-7.
49. Zins BJ, Tremaine WJ, Carpenter HA. Collagenous colitis: Mucosal biopsies and association with fecal leukocytes. *Mayo Clin Proc* 1995; 70:430-3.
50. Jawahari A, Talbot JC. Microscopic and collagenous colitis. *Histopathology* 1996; 29:101-110.
51. Ayata G, Ithamukkala S, Sapp H, Shaz BH, Brien TP, Wang HH, Antonioli DA, Farraye FA, Odze RE. Prevalence and significance of inflammatory bowel disease-like morphologic features in collagenous and lymphocytic colitis. *Am J Surg Pathol* 2002; 26:1414-23.
52. Anagnostopoulos I, Schuppan D, Riecken EO, Gross UM, Stein H. Tenascin labelling in colorectal biopsies: a useful marker in the diagnosis of collagenous colitis. *Histopathology* 1999; 34:425-31.